

**The fusiform face area is not sufficient for face recognition: evidence from a patient  
with dense prosopagnosia and no occipital face area**

Jennifer K.E. Steeves<sup>a</sup>, Jody C. Culham<sup>a</sup>, Bradley C. Duchaine<sup>b</sup>, Cristiana Cavina  
Pratesi<sup>a</sup>, Kenneth F. Valyear<sup>a</sup>, Igor Schindler<sup>c</sup>, G. Keith Humphrey<sup>a</sup>, A. David Milner<sup>c</sup>  
and Melvyn A. Goodale<sup>a</sup>

- a. Department of Psychology  
The University of Western Ontario, London, Ontario, Canada
- b. Vision Sciences Laboratory, Department of Psychology  
Harvard University, Cambridge, MA, USA
- c. Cognitive Neuroscience Research Unit  
University of Durham, UK

Correspondence should be addressed to:

Jennifer Steeves, Department of Psychology,

The University of Western Ontario, London, ON CANADA N6A 5C2

Tel: (519) 661-2111 X88532 Fax: (519) 661-3961

[jsteeves@uwo.ca](mailto:jsteeves@uwo.ca)

Running title: prosopagnosia: FFA but no OFA

### Abstract

We tested functional activation for faces in patient D.F., who following acquired brain damage has a profound deficit in object recognition based on form (visual form agnosia) and also prosopagnosia that is undocumented to-date. Functional imaging demonstrated that like our control observers, D.F. shows significantly more activation when passively viewing face compared to scene images in an area that is consistent with the fusiform face area (FFA) ( $p < 0.01$ ). Control observers also show occipital face area (OFA) activation; however, whereas D.F.'s lesions appear to overlap the OFA bilaterally. We asked, given that D.F. shows FFA activation for faces, to what extent is she able to recognize faces? D.F. demonstrated a severe impairment in higher-level face processing— she could not recognize face identity, gender or emotional expression. In contrast, she performed relatively normally on many face-categorization tasks. D.F. can differentiate faces from non-faces given sufficient texture information and processing time, and she can do this is independent of color and illumination information. D.F. can use configural information for categorizing faces when they are presented in an upright but not a sideways orientation and given that she also cannot discriminate half-faces she may rely on a spatially symmetric feature arrangement. Faces appear to be a unique category, which she can classify even when she has no advance knowledge that she will be shown face images. Together, these imaging and behavioral data support the importance of the integrity of a complex network of regions for face identification, including more than just the FFA—in particular the OFA, a region believed to be associated with low-level processing.

Keywords: fMRI, FFA, OFA, face recognition, prosopagnosia

Total words: 6894

Prosopagnosia is a neurological deficit characterized by an inability to recognize faces despite intact intellectual and cognitive function and spared early visual processing. Cases have been reported where this dissociation occurs with little or no impairment in visual recognition of other types of stimuli (e.g. Duchaine & Nakayama, in press; McNeil & Warrington, 1993; Nunn, Postma & Pearson, 2001; Whiteley & Warrington, 1977). Complementary cases have shown that the converse dissociation, normal face recognition with severe object agnosia, is also possible (Humphreys & Rumiati, 1998; McMullen, Fisk & Phillips, 2000; Moscovitch, Winocur & Behrmann, 1997). Prosopagnosia, however, may also occur in combination with other visual recognition deficits such as an inability to recognize objects and/or words (e.g. Damasio, Damasio, & Van Hoesen, 1982) or landmarks (e.g. Pallis, 1955). The nature of lesions associated with prosopagnosia has long been documented and anatomical and imaging data (CT, MRI, SPECT) from patients with prosopagnosia converge on bilateral inferior occipitotemporal cortical damage (see Farah, 1990 for a summary). This suggests that a relatively localized cortical area is involved in the inability to perceive faces. Whether prosopagnosia occurs in isolation or is accompanied by other agnosias presumably depends on the extent of the cortical damage.

Paralleling neuropsychological evidence, functional imaging in neurologically-intact individuals shows discrete cortical areas that are significantly more active when passively viewing faces than other non-face stimuli such as objects (Kanwisher, McDermott & Chun 1997), letter strings (Puce et al., 1996) or houses (Tonget al., 2000). This area within the fusiform gyrus has been termed the fusiform face area, or FFA

(Kanwisher, McDermott & Chun, 1997). FFA activation correlates well with successful face processing but not with successful object processing (Grill-Spector, Knouf, & Kanwisher, 2004). Similarly, functional magnetic resonance imaging (fMRI) has shown other cortical areas to be selectively more active when viewing other classes of stimuli. This includes objects—the lateral occipital complex (LOC—an area comprising the lateral surface near the lateral occipital sulcus (LO), the ventral occipito-temporal regions (LOa/pFs) extending into the posterior and mid fusiform gyrus and occipito-temporal sulcus) (Malach et al., 1995, Grill-Spector, Kourtzi & Kanwisher, 2001), scenes or places—the parahippocampal place area (PPA) (Epstein & Kanwisher, 1998), letter strings—the left occipitotemporal and inferior occipital sulci (Puce et al., 1996), and the human body— a region in the right lateral occipitotemporal cortex (extrastriate body area or EBA) (Downing et al., 2001). Early studies of face-selective activation in the cortex saw that, in addition to the FFA, other cortical areas were selectively active for faces, specifically in the superior temporal sulcus (STS) and in the inferior and mid occipital gyri (e.g. Halgren et al., 1999; Haxby et al., 1999; Kanwisher, McDermott & Chun, 1997; Vaina et al., 2002) although in some studies these areas appeared to be less systematically activated (e.g. Kanwisher et al., 1997) or showed a weaker face-selective response (Gauthier et al., 2000) than the FFA. The importance of the inferior occipital area in face processing has been, until recently, somewhat overlooked for these reasons and also because it is a relatively "early" visual area in the ventral stream—earlier areas are assumed to perform lower-level processing rather than higher-level processing such as face recognition. Gauthier et al. (2000) termed the face-selective inferior occipital area that falls within the larger LOC region, the occipital face area (OFA).

Consistent with the notion of discrete brain areas for processing such image classes as faces, objects and scenes, behavioral evidence in neurologically-intact participants suggests that qualitatively different cognitive processes are involved. For example, the attentional demands of scene and object processing appear to be different (Li et al., 2002). Other behavioral measures show face-specific effects of visual processing that do not affect other image categories. For instance, rotating a face image upside-down disturbs face recognition ability more than object recognition (Yin, 1969). In contrast, the ability to classify a scene image correctly is not significantly affected by inverting it (Steeves et al., 2004). Further, face recognition appears to involve more holistic processing than object recognition, which can often operate using more part-based mechanisms. For example, individual parts of a face are more accurately recognized when presented within the whole face rather than in isolation. This is not the case for other types of stimuli such as scrambled faces, inverted faces or houses (Tanaka & Farah, 1993).

It seems intuitive to expect then that damage to these brain areas would result in domain specific agnosias. To a certain degree, this does appear to be the case. Topographical agnosia patients, who have damage localized to the region of the PPA, are impaired in scene recognition but not object recognition and do not show functional activation for scene images in this brain region (Epstein et al., 2001). Consistent with this notion our research group recently performed MRI and fMRI scans on a patient, D.F. who suffers from profound visual form agnosia (a deficit in object recognition based on form). It was revealed that her area of damage overlaps with the object-selective lateral-occipital area (LO) of the LOC in normal participants in both hemispheres (James et al.,

2003). We also recently examined functional activation for scenes in patient D.F. and observed that despite an absence of object recognition she had relatively normal scene recognition ability and PPA activation (Steeves, et al., 2004). In that paper, we also observed that D.F. showed what appeared to be normal functional activation for faces in an area consistent with the FFA. However, it has been informally noted that patient D.F. has an inability to recognize faces. If she can not recognize objects and has no LO but can recognize scenes and has an intact PPA, why can she not recognize faces when she shows functional activation in the FFA? Here, we extensively examine her inability to recognize faces given that she demonstrates FFA activation for faces and find that D.F. has spared face categorization but no higher-level face processing abilities. We speculate that since her bilateral LO lesions overlap with the OFA bilaterally, an intact network between the FFA and the OFA may be necessary to drive higher-level face processing.

## Methods

### Patient History:

D.F. is a female patient, age 47 years, who suffered brain damage as a result of accidental carbon monoxide poisoning at age 34. D.F. shows relatively normal perimetry for static targets in the central visual field up to 30° eccentricity but with some lower visual field loss. Details of extensive neuropsychological and sensory testing of D.F. are described in Milner et al. (1991). She has profound visual form agnosia (a deficit in object recognition based on form) which has also been detailed elsewhere (Milner et al., 1991). D.F. has great difficulty perceiving the shape, size and orientation of objects, as well as in recognizing or copying line drawings of objects (Servos et al., 1993). She can discriminate, however, amongst hues and name colors appropriately (Milner & Heywood, 1989). As a result, D.F. can recognize *real* objects, particularly natural objects such as fruit and vegetables, based on surface information such as color and visual texture (Humphrey et al., 1994). It has been noted that D.F. is unable to recognize the faces of people familiar to her during previous neuropsychological examination (Milner et al. 1991) although this prosopagnosia has not been extensively quantified to date. Patient D.F. behaves like a prosopagnosic in that she recognizes people that are familiar to her on the basis of non-face cues such as clothing, hair, stature, gait, and voice, for example. In addition, D.F. does not respond to facial expression in her interaction with others.

Recent brain imaging data suggest that D.F.'s deficits in form vision are largely a consequence of localized damage to occipito-temporal regions involved in object recognition. Magnetic resonance imaging (MRI) carried out one year after the accident

revealed a distributed pattern of brain damage consistent with anoxia, but the damage was most evident in the lateral occipital cortex and the medial occipitoparietal region (Milner et al., 1991). Our research group had the opportunity to perform additional MRI and fMRI scans of D.F. in 2001 (Culham, 2004; James et al., 2003). An examination of the anatomical MRI images suggested three main lesions, one in the lateral occipital (LO) cortex of each hemisphere and one in the left hemisphere near the top of the parieto-occipital sulcus. The location in stereotaxic space (Talairach & Tournoux, 1988) of D.F.'s bilateral lateral occipital lesions overlap almost completely with fMRI activation of LO in normal observers viewing images of objects. In other words, D.F.'s lesions are localized in the very regions of the occipitotemporal cortex that have been implicated in the visual processing of objects (James et al., 2003). Although D.F.'s anatomical scans reveal a widening of the sulci throughout the cerebral cortex, fMRI showed normal activation in visual cortex and dorsal stream regions that appear to subserve her preserved visuomotor abilities such as grasping (Goodale & Milner, 1992). This clear dissociation between perception and action in a brain-damaged patient has been a great contribution to the current distinction between ventral and dorsal streams for processing perception and action, respectively.

**Control participants:**

For the functional imaging, we tested three normal healthy control participants (mean age = 30 years). For the behavioral tests of face perception, sixteen male and female undergraduates and two female age-matched controls (age 46 and 57 years)



served as control participants for most tests. For some tests, we did not include a control group.

### **FMRI investigation of activation for face images**

#### **Stimuli:**

This dataset was originally used to investigate functional activation for scenes, and therefore full details of fMRI methods can be found elsewhere (Steeves et al., 2004). Also our functional imaging of D.F.'s brain included several different scene image conditions in addition to face images. During fMRI, D.F. viewed visual images of faces, normally colored scenes, grayscale scenes, black and white scenes, or a fixation stimulus alone. The face stimuli consisted of color images of famous faces, 8 male and 8 female, seen from a frontal viewpoint on a black background. Scene images were taken from a CD photo image library. Faces and scenes subtended approximately the same retinal image size (12 deg). Each stimulus epoch lasted 16 seconds, during which 16 different stimuli were presented for one sec each. Each stimulus condition was repeated four times within each run (with a fixation period every fifth epoch) in pseudo-random order. Two runs were obtained on D.F. For the control participants, the functional run presented blocks of 16 sec of fixation alternating between blocks of either 16 one sec face images or 16 one sec colored scene images, repeated for four cycles. In order to maintain attention, both D.F. and neurologically-intact participants were asked to press a button when they perceived a “forest” scene.

#### **Data acquisition:**

Scans were conducted with a 4-Tesla Siemens-Varian whole-body MRI system at the Robarts Research Institute using blood oxygenation level dependent (BOLD) imaging and a head coil for functional images. A series of sagittal T1-weighted scout images were acquired to select 17 contiguous, 5 mm thick functional slices in a quasi-coronal orientation, sampling the occipital and posterior temporal cortex. Each functional volume was acquired using a navigator-echo-corrected, slice-interleaved multishot (2 shots) echo planar imaging (EPI) pulse sequence with a 64 x 64 matrix size and a total volume acquisition time of 2 s [TE=15ms, flip angle=45 deg, FOV=19.2 cm]. Each imaging run consisted of 140 consecutive acquisitions of the selected brain volume. Within the same imaging session, high-resolution inversion-prepared 3-D T1-weighted anatomical images were acquired (64 slices, 256 X 256, 0.75 X 0.75 X 3 mm voxel size, TR = 9.8 ms TE = 5.2 ms). In another session, participants were scanned using a cylindrical quadrature birdcage-style radio-frequency (RF) coil. Functional images were manually realigned to high-resolution anatomical images (1 X 1 X 1) that sampled the whole brain in order to obtain full-brain anatomical images to allow computation of stereotaxic co-ordinates (Talairach & Tournoux, 1988).

**Image Analysis:**

Analyses were carried out using Brain Voyager 4.6 software and functional images underwent linear trend removal. General linear model analyses were performed with separate predictors for each stimulus condition. Contrasts between predictors were used to identify regions of interest (e.g., +faces, -scenes). Areas were defined as all of the contiguous activated voxels in the vicinity of the appropriate anatomical area that met a minimum threshold of  $p=0.0001$  for the FFA and  $p=1.7 \times 10^{-8}$  for the PPA. Because the

functional run for D.F. included several scene conditions, for her we defined the FFA and PPA using the contrast between all three scene stimuli and the face stimuli. For control participants, the FFA and PPA were defined as a contrast between faces and scenes.

**Results:**

Anatomically, D.F. shows a pattern of diffuse brain damage, which is common with hypoxia, but the concentration of damage is in bilateral ventral lateral-occipital cortex. The lesion is larger in the right than in the left hemisphere. There is also a smaller lesion in occipito-parietal region in the left hemisphere. The enlarged ventricles and sulci throughout the brain indicate atrophy. Despite the abnormal appearance of regions outside the lesions, previous data indicates that these areas continue to show functional activation (i.e. James et al., 2003; Steeves et al., 2004).

In all observers, including D.F., viewing faces produced greater activation in an area consistent with the FFA than did viewing scene images ( $p < 8.6 \times 10^{-8}$ ). Viewing scene images produced greater activation in the PPA than did viewing faces ( $p < 0.01$ ). Face images also produced greater activation in other cortical areas including STS in both D.F. and controls, and the OFA, but in the controls only. In fact, the OFA appears to be located well within D.F.'s bilateral LO lesions—see panel C of Figure 1. Our Talairach coordinates for these areas are consistent with those of earlier studies and are listed in Table 1 below. Figure 1 shows FFA activation on the ventral surface of D.F.'s brain rendered at the pial surface (A) as well as STS activation (C) but no OFA activation (D) is seen in either hemisphere. The dark gray areas in D.F.'s rendered brains (A, B) show the location of her LO and PO lesions. In the control observer, face-selective activation is seen in the FFA (A), STS (C) and the OFA (B, D). The red line shown on the rendered

brains in B represents the z-plane through which the locus of STS activation occurs in D.F. and the control. The blue line represents the z-plane of the OFA activation in the control observer. This same z-plane is mapped onto D.F.'s brain in B and it is clear that the OFA is well within D.F.'s LO lesion. There were small clusters of activation in each hemisphere of D.F.'s brain that did not overlap with the OFA of our controls but were relatively nearby. In the left hemisphere, there were two small clusters on the border of her lesion that measured  $0.08 \text{ cm}^3$  and  $0.05 \text{ cm}^3$  but were more anterior and inferior than the OFA of our control subjects [Talairach coordinates— cluster 1: -41, -67, -14; cluster 2: -38, -72, -14; mean OFA controls: -40.7 (2.5), -79.3 (2.9), -9.7 (3.2)]. In the right hemisphere, there was a larger region of face-selective activation measuring  $0.9 \text{ cm}^3$  that was more lateral than the OFA of our controls [Talairach coordinates— 50, -70, -8; mean OFA controls: 36.7 (7.1), -74.7 (6.1), -9.7 (6.1)].

In order to better illustrate the bilateral FFA face-selective activation in patient D.F. Figure 2 shows axial slices through the FFA and STS in both D.F. and a control subject. The activation that D.F. shows in the FFA is similar in the two hemispheres and is comparable to that seen in the control subject. STS cluster size is larger in patient D.F. than in the control. The average time courses for face-selective activation are also shown in Figure 2. Patient D.F. shows similar face-selective BOLD signal to that of the control— around 1%. Both D.F. and the control subject demonstrate larger % BOLD signal change in the FFA than the STS.

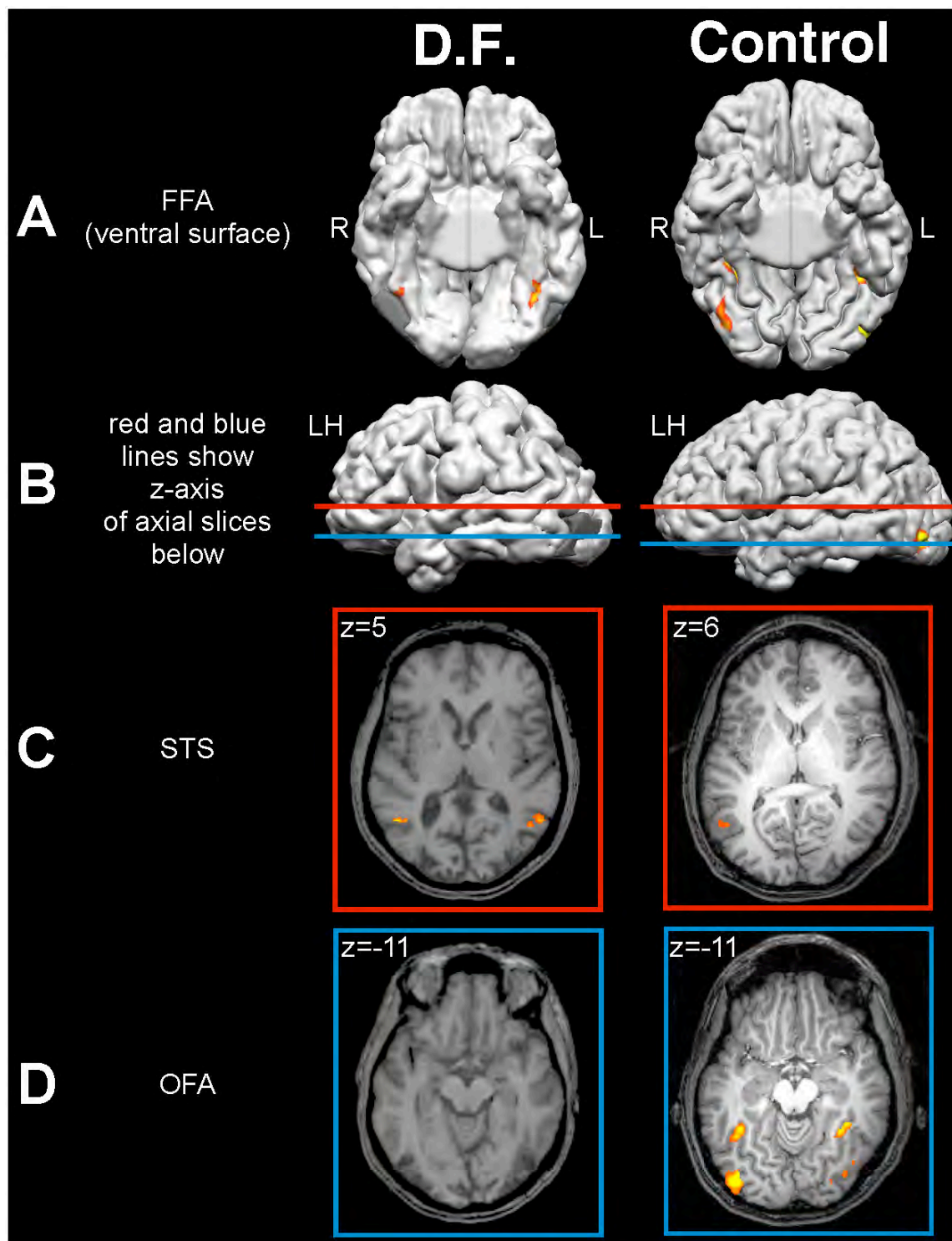


Figure 1. Functional activation for face images in D.F. and one control subject. (A) FFA activation on the ventral surfaces. Dark gray areas of D.F.'s rendered brain in (A) and (B) show the location of her LO and PO lesions. (B) The red line shown on the left

hemisphere represents the z-plane through which the locus of STS activation occurs in D.F. and the control. The blue line on both brains represents the z-plane of the OFA activation in the control observer which clearly runs through D.F.'s LO lesion. (C) STS activation on an axial slice. (D) OFA activation in the axial slice in the control but no OFA activation is seen in either hemisphere of patient D.F.

Table 1. Talairach coordinates (x, y, z) of brain regions with stronger responses to faces than places in each subject.

Subject		FFA	OFA	STS
Patient D.F.	LH:	-37, -56, -21		-46, -56, 5
	RH:	40, -54, -20		52, -55, 5
Control 1	LH:	-39, -53, -19	-41, -81, -6	-45, -70, 8
	RH:	37, -54, -16	43, -76, -3	
Control 2	LH:	-33, -49, -16	-38, -76, -12	
	RH:	39, -49, -17	29, -80, -11	56, -48, 29
Control 3	LH:	-42, -47, -11	-43, -81, -11	-54, -58, 6
	RH:	33, -42, -12	38, -68, -15	

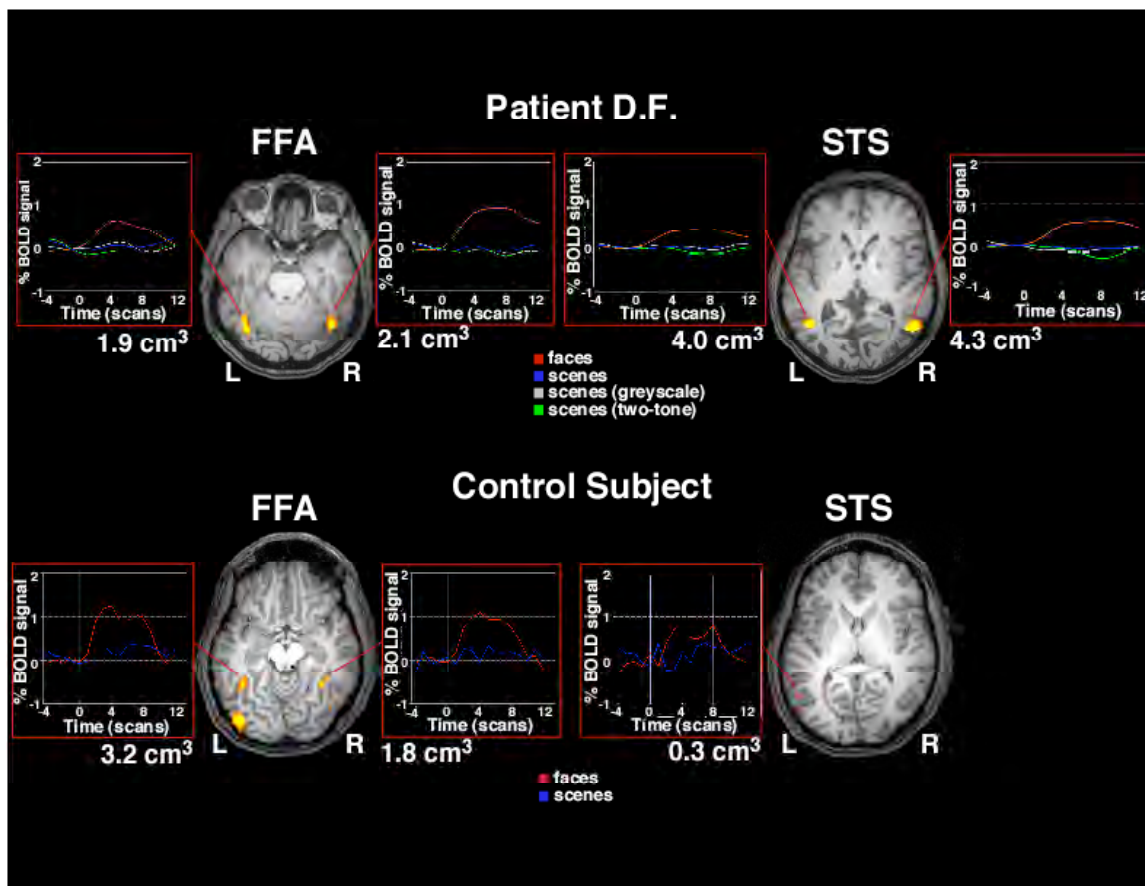


Figure 2. Axial slices through the FFA and STS in both D.F. and a control subject demonstrating clear bilateral face-selective FFA activation in D.F. Event-related average time courses for face-selective activation are also shown. Activation cluster size is indicated below the time course.

## Testing of Face Perception

### Stimuli:

For all tests, stimuli were presented on a 17" display or a 15" laptop display. Depending on the particular test, stimuli subtended approximately 4 to 8 degrees visual angle.

Subjects indicated a response by pressing the left or right mouse button or by pressing designated keys on a keyboard. In some cases, the experimenter recorded the subject's response and as a result latencies were not measured. Stimuli were presented using Superlab 2.0, Cedrus Corporation. Generally, trials were self-paced and conditions were pseudo-randomized.

## Methods and Results

### *Face categorization:*











#### 1) Face/non-face categorization with color/texture manipulation

We designed a task to determine whether D.F. could discriminate a face from an object and what role color and texture might play if such an ability exists, since for this patient colour and texture contribute to her ability to classify scenes (Steeves et al., 2004). One hundred and twenty two-alternative temporal forced-choice face/object pair trials were presented (25 trials of each pair—gray faces/gray objects, natural colored faces/natural colored objects, natural colored faces/flesh-tone colored objects and gray faces/flesh-tone colored objects and 20 trials of line drawings of faces and objects). Stimuli were presented for 100 ms each. The table below shows examples of stimuli from each face/object pair. If color and texture are important for D.F. to discriminate faces as they are for scene classification (Steeves et al, 2004) we predicted that she would be at



chance for three face discrimination conditions— gray faces/gray objects where no color information was available at all; naturally colored faces/flesh-tone colored objects where both objects and faces had flesh-tone coloring; and line drawings of faces and objects where no colour information was available and in addition, texture information was at a minimum. We predicted that D.F. would make a larger number of errors for gray faces/flesh-tone colored objects where faces were grayscale and objects were in flesh-tones, and that she would perform above chance for naturally colored faces/colored objects where faces and objects were naturally colored. D.F., surprisingly, was able to discriminate a face from an object 95% overall. See table 2 below.





Table 2. Face/non-face categorization with color/texture manipulation Examples of stimuli used for each face/object pair condition. Percent correct for each condition is shown in the far right column,

face/non-face comparison				% correct
gray face		gray object		88
natural face		colored object		96
natural face		flesh-tone object		100
gray face		flesh-tone object		96
line-drawing face		line-drawing object		95

## 2) Free form image description

Because D.F. was able to easily discriminate a face from an object in test 1 using a forced-choice paradigm, this test was designed to determine, in a non-forced choice design, whether faces are indeed a uniquely identifiable category for her. This test was conducted 1 year after the previous face categorization test and DF was not told ahead of time that some of the stimuli would be faces. There were two test versions—grayscale and line drawing, each containing 30 test images, 25 of which were objects such as a bathtub, coffee cup or kettle, while five were faces. Face images were in a frontal or near-frontal view and 35% of grayscale images and 65% of the line drawings of objects were spatially symmetric. Different objects and faces were used in each version. D.F. was asked to describe what each image was. Images remained on the screen until she responded. In both the line drawing and grayscale versions of this test, D.F. accurately identified all five face images as "a face" but none of the objects.

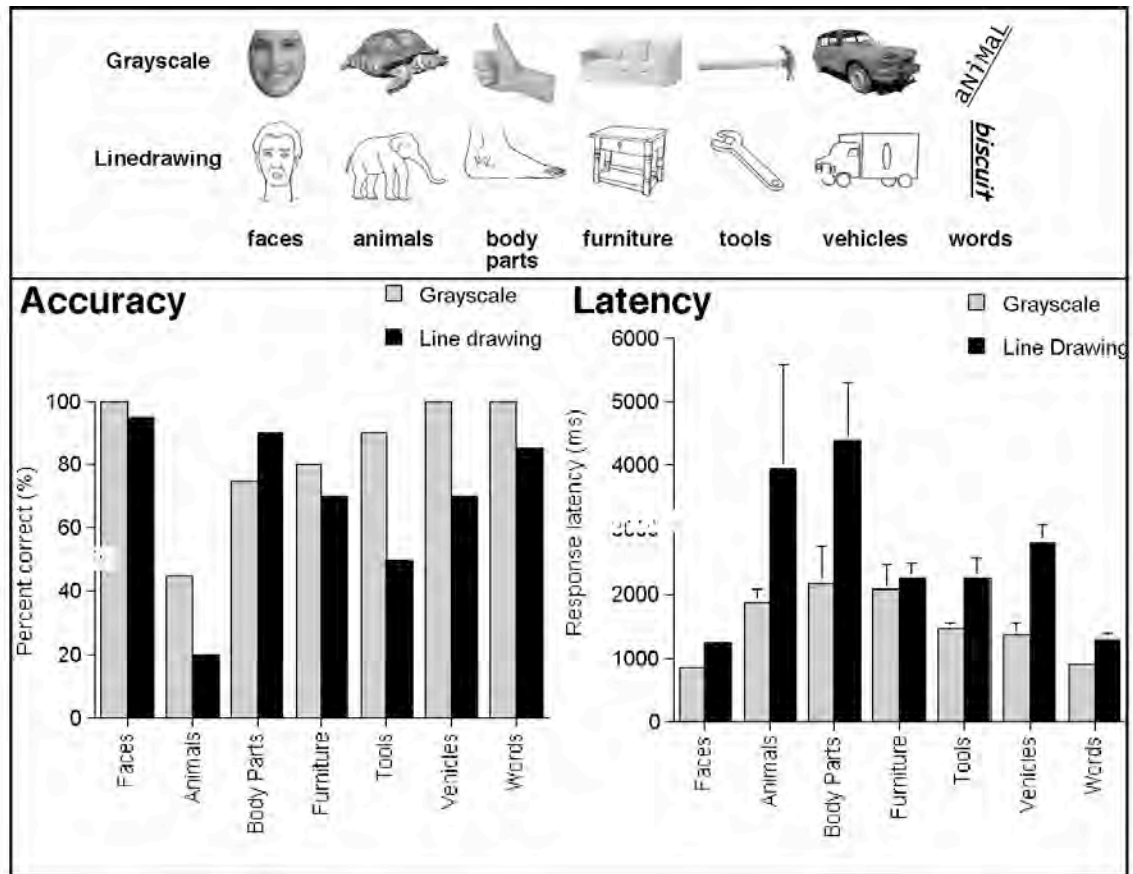
Table 3. Free form image description. Examples images from each version. Percent correct is shown in the far right column.

	test version		% correct
grayscale	object		0
	face		100
line-drawing	object		0
	face		100

### 3) Multiple-Category Categorization

Subjects were required to categorize images to one of seven categories— faces, animals, body parts, furniture, tools, vehicles, and words. Categories were divided into two blocks and faces were repeated in each block so that there were four categories per block. (Block 1: animals, furniture, tools, faces; Block 2: body parts, vehicles, words, faces.) There were two test versions per block—a grayscale and a line drawing version, the order of which was counterbalanced. Grayscale images were taken from the Hemera Photo Objects Premium Image Collection, Hemera Technologies Inc. See top panel of Figure 2 for examples from each category and version. There were 20 different test images per category in each block and test version, giving 80 images per run.

D.F. accurately categorized faces in both the grayscale and line drawing versions of the test, 100 and 95% correct, respectively. She also accurately categorized whole words in each test version at 100 and 85% correct, respectively. See bottom left panel of Figure 3. When asked how she performed the task, D.F. said that it was easy to recognize a face and a word, so she used an exclusion process for the other categories. For example, she suggested that images that were long in extent were likely to be tools while rectangular images were likely to be furniture or vehicles. This meant that the most difficult categories for her, body parts and animals, could be derived by exclusion of the other categories. This is well evidenced by response latencies, which demonstrate this speed accuracy trade-off. That is, despite high accuracy rates for many categories, correct response latencies were fastest for faces and words but much slower (approximately 2 - 4 times) for other categories. Repeated measures analysis of variance (ANOVA) demonstrated that there was a significant difference in correct response latencies between categories [grayscale:  $F(6, 114) = 5.75$ ;  $p \leq 0.01$ ; line drawing:  $F(6, 126) = 15.45$ ;  $p \leq 0.01$ ]. For both grayscale and line drawing test versions D.F. was fastest at categorizing faces compared to all other categories (t-tests,  $p \leq 0.01$ ) except words (grayscale:  $t(36) = 1.69$ ,  $p = 0.09$ ; line drawing:  $t(30) = 1.7$ ,  $p = 0.37$ ). D.F. was also faster overall at categorizing grayscale images compared to line drawings [ $F(1,21) = 71.89$ ;  $p \leq 0.01$ ]. See bottom right panel of Figure below.



**Figure 3.** Grayscale and line drawing examples from each of the seven image categories are shown above. Performance accuracy and latency for each image category are shown below in the left and right panels, respectively.

#### 4) Upright/inverted face discrimination

In a spatial 2AFC design, two face images were presented side by side—one was upright while the other was upside down. The subject was asked to indicate, as quickly as possible, whether the image on the left or the right was upright. There were 40 face pairs and each remained visible until the subject responded. Faces were grayscale and pairs were matched so that illumination of the face was from the same direction in each image pair in an attempt to eliminate this as a potential orientation cue. An example is shown in

the Figure 4. We also used a single trial yes/no paradigm, where subjects were presented a face and were asked to indicate whether the face was upright or inverted. There were two versions of this test, one where face images were presented for 100 ms and another where faces remained visible until the subject responded. Subjects viewed 60 face images in each run—half were inverted. In the spatial 2AFC design, D.F. was able to discriminate an upright from an inverted face at near normal levels—see left panel in Figure 3. Similarly, D.F.'s sensitivity was also near normal on the yes/no task when given unlimited viewing time. With a brief stimulus presentation, however, D.F. was unable to discriminate an upright from an inverted face—see right panel of figure 4.

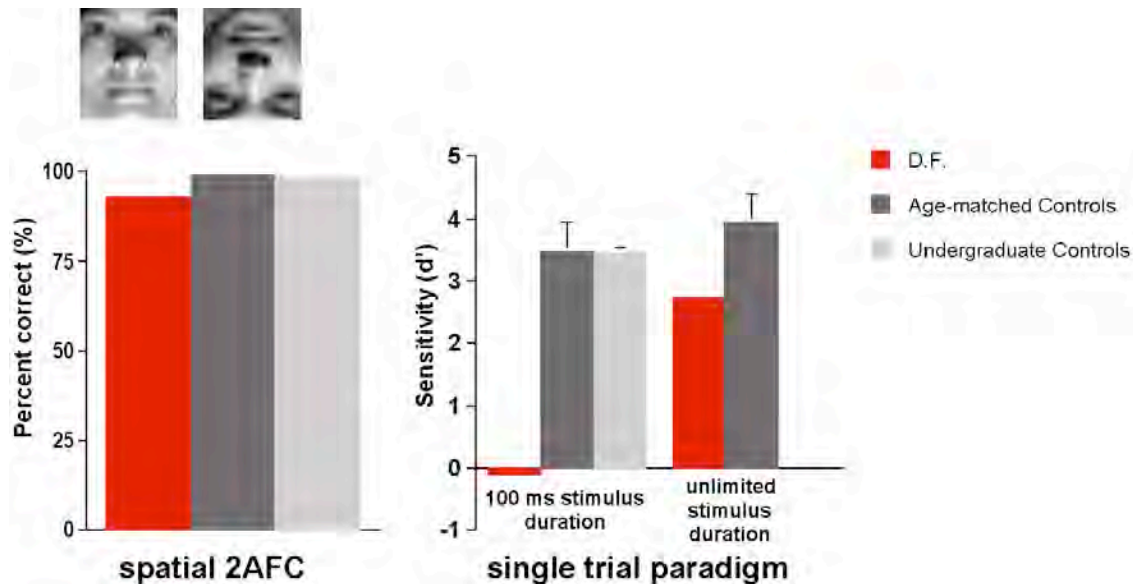


Figure 4. Above, an example of an upright and inverted face which both have the direction of illumination from below. Below, D.F.'s accuracy and sensitivity performance for each test version compared to controls.

##### 5) Scrambled faces

Using a single trial yes/no paradigm, subjects were presented a grayscale face with features in the normal arrangement or a face in which the features had been rearranged (scrambled) so that a mouth might appear where an eye should be, for example (see Duchaine et al., 2003 for full details). Here, there were also two cases of feature rearrangement for the scrambled faces—one in which the normal T-shaped feature configuration (two eyes laterally at the top with a nose and mouth in line below) was maintained and one in which features were rearranged in different positions—see Figure 5 for examples. There were two versions of this test, one in which face images were presented for 100 ms and another in which faces remained visible until the subject responded. We ran a second block of the two test versions in which all of the face stimuli were rotated 90 deg in an attempt to determine the importance of the orientation of the T-shaped feature arrangement. When scrambled faces were presented upright and for an unlimited time, D.F. was able to discriminate a normal face from those with rearranged features, although not at a completely normal level. She was able to correctly reject all but one scrambled face. See left panel of Figure 5. When faces were oriented sideways, D.F. was unable to discriminate a scrambled from a normal face no matter what the viewing time. Control observers' performance was little affected by this change in orientation. See right panel of Figure 5.

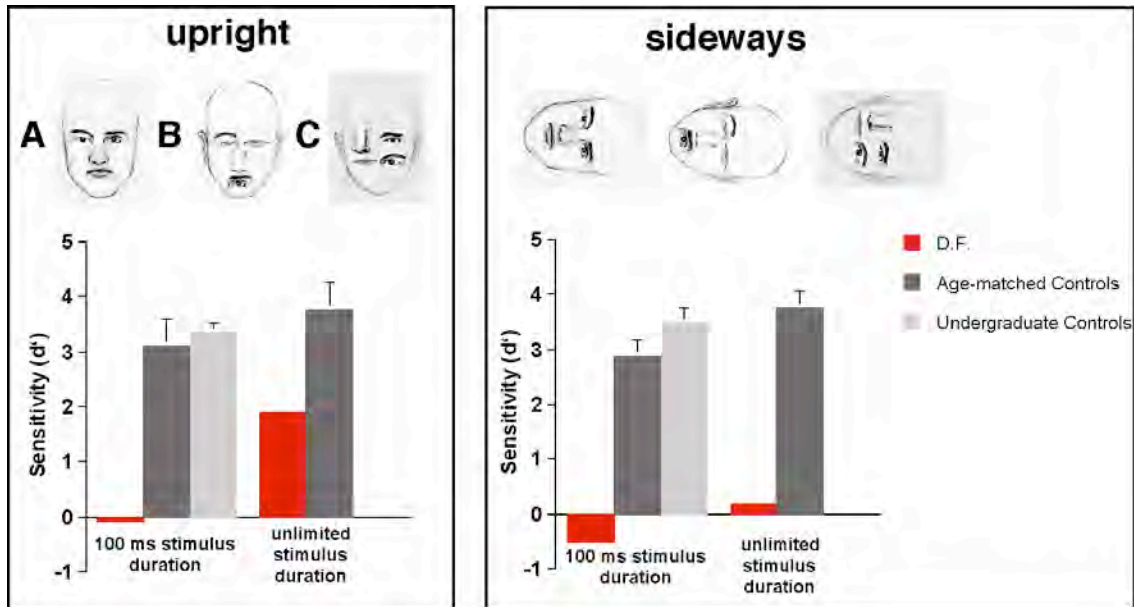


Figure 5. Example images from the scrambled faces test: A—a normal face with features in the normal arrangement, B—a scrambled face where the features have been rearranged (scrambled) so that an eye appears where the mouth should be, and C—a scrambled face where features are rearranged in different configuration. Sensitivity is shown below for each stimulus duration.

#### 6) Half-faces

Given the findings of the previous test, we needed to further address whether or not D.F. was using the T-shaped symmetrical arrangement of the features in a normal face configuration for categorizing an upright from an inverted face. We presented faces that were partially occluded by a vertical black bar that covered half the face from the midline to the side. See Figure 6. Sixty grayscale faces were taken from the set of normal faces in the scrambled faces test. Faces were presented in an upright or inverted orientation for an unlimited viewing time until the subject indicated whether the face was upright or upside down. D.F. was unable to discriminate an upright from an inverted face



when it was partially occluded from the midline. Her discrimination performance, 58% correct, was near chance.




Figure 6. Partially occluded faces presented in an upright (A) or inverted (B) orientation.

#### 7) Mooney face/non-face discrimination

In a spatial 2AFC design, a Mooney-like face and non-face were presented side by side. The subject was asked to indicate, as quickly as possible, whether the image on the left or the right was a face. [Mooney non-face and face images were taken from the Mooney Closure Test (Mooney, C.M., 1956).] An example pair is shown in Figure 7. Three blocks of fifteen face/non-face pairs were presented. Images were visible on the screen until the subject responded and latencies were measured. Even though stimuli were visible for an unlimited amount of time, D.F. was near chance at discriminating a Mooney face from a non-face. Control observers' performance was near 100%. See Figure 7.

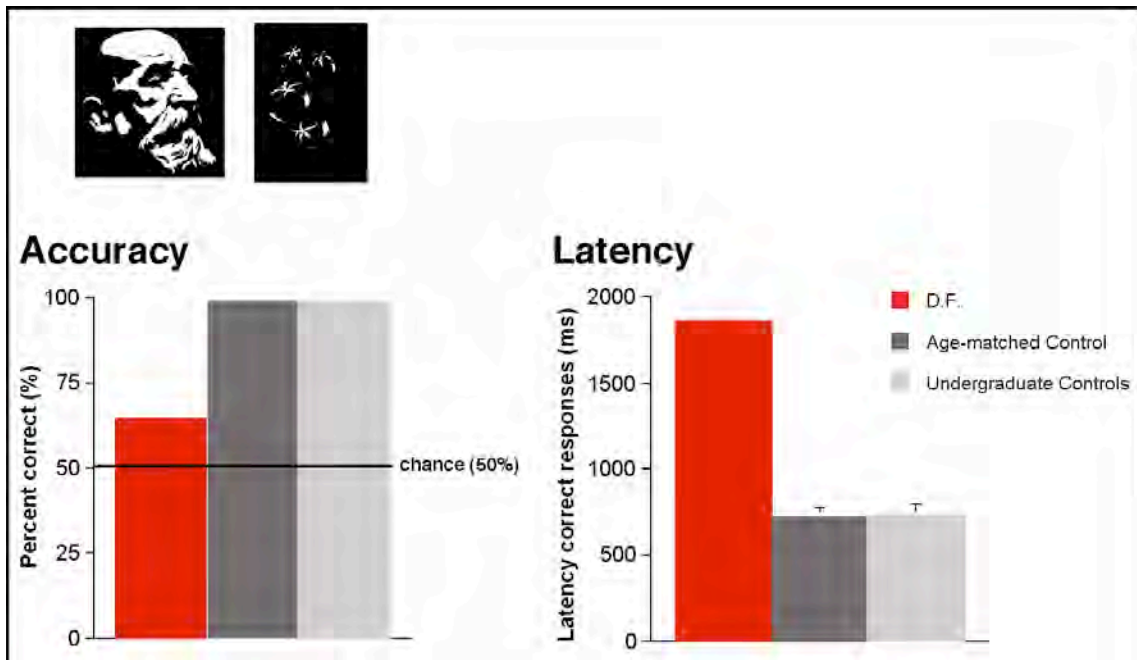


Figure 7. At top, a Mooney face/non-face pair—a face and a group of tomatoes. D.F.'s accuracy and latency performance are shown below.

#### 8) Upright/inverted Mooney face discrimination

In a spatial 2AFC design, subjects were shown 20 Mooney face pairs from the set in the previous experiment. One was upright and the other upside down. Subjects were asked to indicate whether the image on the left or the right was upright. See Figure 8 for an example. Similar to her performance on Mooney face/non-face discrimination, D.F. was unable to discriminate an upright from an inverted Mooney face. (See Figure 8).

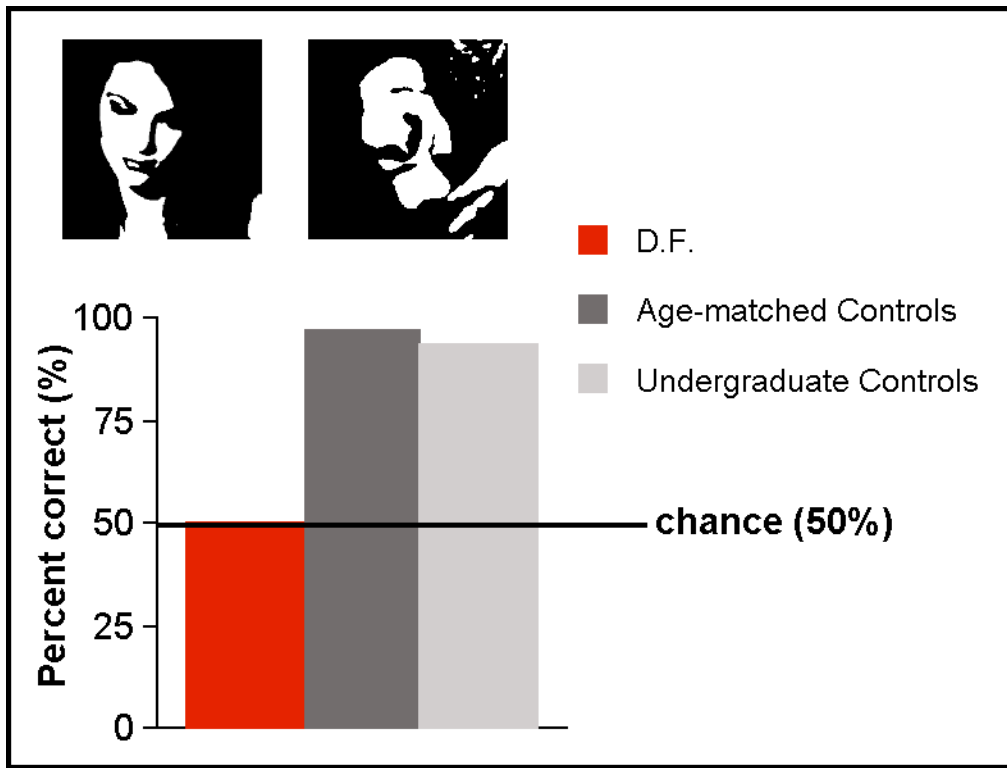


Figure 8. An example of an upright and inverted Mooney face. D.F.'s accuracy is shown below.

#### 9) Detection of composite faces in art

We showed patient D.F. a series of twelve paintings by Italian artist Giuseppe Arcimboldo, which were images of faces composed of objects (see below left for an example). We asked her to describe what she saw. D.F. was only able to recognize one of the twelve paintings (Figure 9, right) as that of a face. She described the painting below as "a man with a funny hat on".



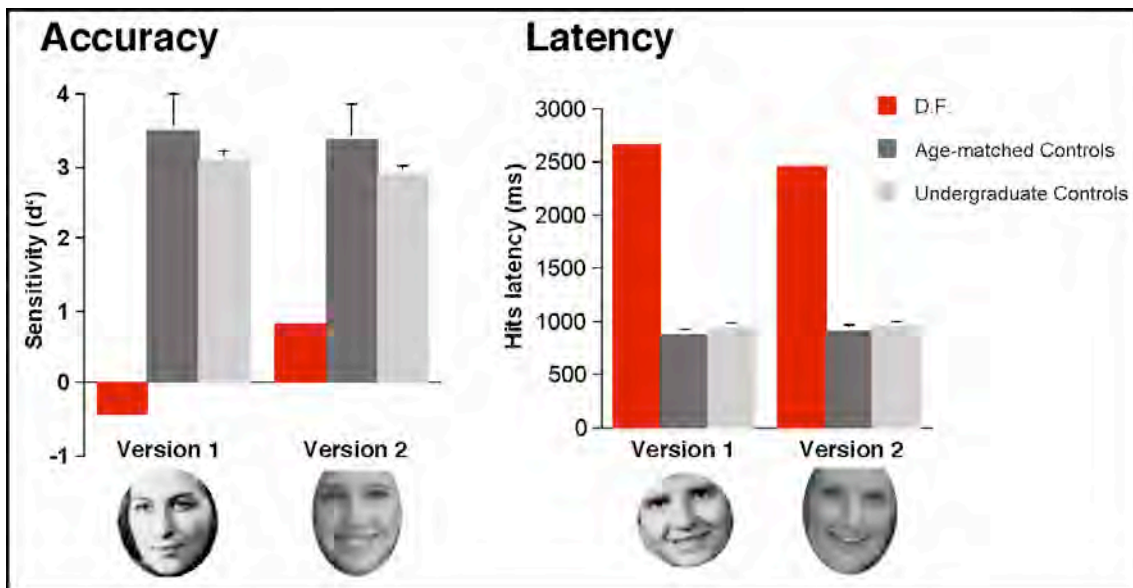
Figure 9. "Autumn" (L'autunno) by Giuseppe Arcimboldo, 1573

*Higher-level face processing: Face recognition*

1) Old/New face discrimination

Two versions of old/new face discrimination tests were used that consisted of two different sets of grayscale frontal view photographs of female faces (see Duchaine, et al., (2003) and Duchaine & Nakayama, in press for full details of the test). Figure 10 shows examples from each old/new discrimination test version. Participants studied ten target faces and were then asked with a series of single images to judge whether each was one of the previously studied target faces or a new non-target face. Each target face was shown twice (20 target presentations, 30 non-target presentations) within the test phase. D.F. scored very poorly on both versions of face old/new discrimination compared to controls. On both versions, using signal detection, her false alarm rate was higher than her hit rate. On version 2, D.F. also had a higher tendency to respond "yes" than "no" since her false alarm rate significantly exceeded her miss rate. Further, D.F.'s response

latencies were more than twice as slow as that of control observers. These slower response latencies cannot be attributed to slower motoric responses since D.F.'s movement kinematics for reaching and grasping are within normal limits (Goodale, Jakobson & Keillor, 1994) but rather must be attributed to her difficulty with the task of face recognition. Other cases of prosopagnosia show long response latencies for face recognition as well (Duchaine, 2000, Newcombe, 1979, Nunn et al., 2001). Results are shown in the Figure 10.



**Figure 10.** Example face images that were used in each old/new face discrimination test version are shown below the graphs of performance accuracy and latency.

Since D.F. was unable to recognize faces in a basic old/new paradigm, we have included the results of two other tests of face recognition, which controlled for potential cues for face recognition that the basic old/new paradigm did not, in the supplemental information. In summary, one of these tests required face matching across different

directions of illumination and the other tested for face matching from a frontal to a 3/4 profile view. D.F. was unable to recognize faces in either of these tests.

#### 4) Recognition of Famous Faces:

Participants were presented 60 images of famous individuals such as Margaret Thatcher, John F. Kennedy, Princess Diana, Martin Luther King, and Audrey Hepburn who would have been known to D.F. prior to her brain injury. (See Duchaine (2000) for full details of this test.) Subjects were asked to name the individual or to give any information such as the individual's profession that could uniquely identify the face image. Images were presented for 5 s and trials were self-paced. D.F. was unable to recognize any of the famous faces. In contrast, the two age-matched controls were able to identify on average 93% of the set of famous faces. Yet D.F. was knowledgeable of famous individuals, and offered names such as 'Woody Allen' and 'Marilyn Monroe'. Further, since D.F. was unable to correctly name any of the famous faces we asked her to simply make a basic level gender classification for each famous face. She could not, however, reliably say whether a face was male or female.




Figure 11. Examples of famous faces shown in the test of famous face recognition. \

#### *Higher-level Face Processing: Gender Discrimination:*

Version 1: Subjects were shown 200 color face images—100 male and 100 female.

Faces were provided by the Max-Planck Institute for Biological Cybernetics in Tuebingen, Germany. Subjects were required to indicate whether the face was male or female and images remained visible until the subject responded. Version 2: Subjects also were tested on their ability to discriminate the gender of grayscale faces embedded in spatial noise. Forty male and 40 female faces were presented for 300 ms each. Example images in each version of the gender discrimination test are shown below. D.F. performed poorly on both versions (color and grayscale) of the gender discrimination task while controls performed these tasks reasonably well. (See Figure 12).

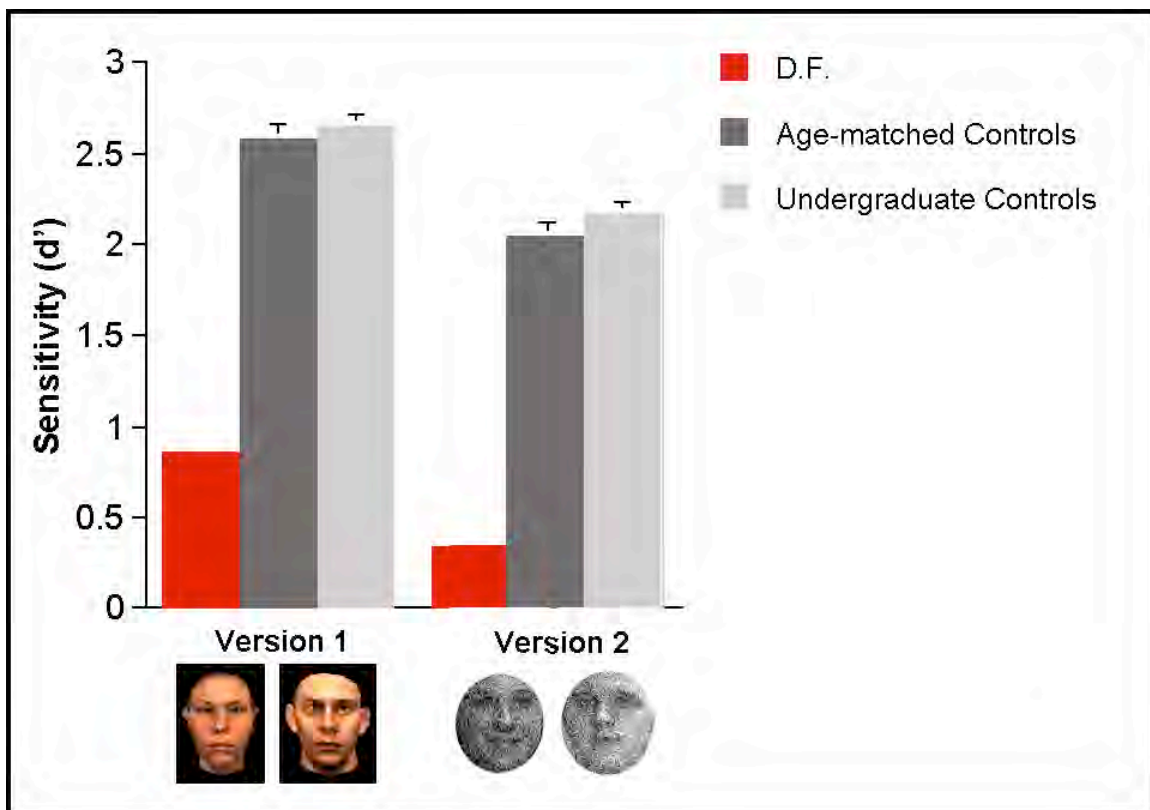


Figure 12. An example of a female and a male face image for each gender discrimination test version.

*Higher-level Face Processing: Recognition of Emotional Expression:*

Using a spatial 2AFC design, subjects were shown 60 pairs of faces. In one run, subjects were asked to discriminate between the face that showed a happy facial expression and another facial expression. In another run using different face pairs, subjects were asked to discriminate between the face that showed disgust/displeasure and another facial expression. We tested recognition of both happiness and disgust/displeasure since there can be a dissociation between recognition of these two emotions in some neurological patients (Sprengelmeyer et al., 1996). Controls' discrimination performance was at 88% or higher while D.F.'s performance was near chance. (See Figure 13).

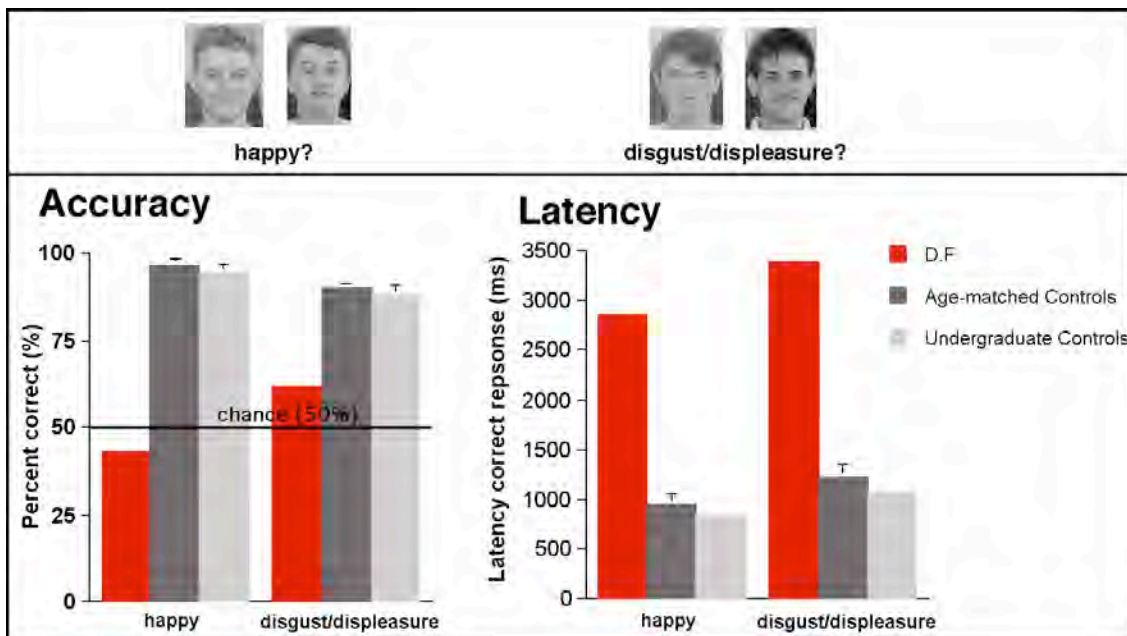


Figure 13. The top panel shows an example of face pairs where, on the left one face exhibits a happy facial expression and on the right, one face shows disgust/displeasure. Accuracy and latency performance for D.F. and controls is shown below.



*Shape/ Pattern Recognition:*

It has been demonstrated in healthy controls that concentric patterns are more effective at activating the FFA than radial and conventional vertical sinusoidal patterns (Wilkinson et al., 2000). Since D.F. has an intact and functionally active FFA we thought she might be able to recognize circular patterns but not lines and also discriminate circular from radial patterns. In a match-to-sample design, we tested D.F.'s ability to recognize patterns or shapes. She was shown a pattern/shape for 2s and then a pair of patterns/shapes appeared for an unlimited viewing time. Matching pattern/shape pairs were as follows: horizontal or vertical bars, oblique bars clockwise or counterclockwise, radial or concentric patterns and hyperbolic patterns at 0 or 90° orientation. Spatial frequency of each pattern was varied. Twelve of each pattern/shape pair was presented. D.F. was unable to recognize shapes in the match-to-sample pattern task—her performance was just below chance (Figure 14). We speculated that since the concentric and radial patterns were both contained within a circle and similarly, since the other patterns were contained within a square, this may have been too difficult a judgment to make. We then designed a more straightforward 4-alternative forced-choice shape discrimination task, in which we showed patient D.F. pictures of open or filled circles, squares, diamonds and triangles. She was told the four possible shape categories in advance and viewed nine shapes from each category. She was able to categorize most basic shapes in this simpler task, given the 4 categories in advance. Her performance for categorizing circles and squares was 100 per cent and for triangles, 89 per cent correct. Diamond shapes were the only difficult shape (55 % correct), which were most frequently confused for a triangle. Comparing D.F.'s ability on these two shape/pattern

recognition tasks, she was better able to make discriminations when stimuli differed in their overall global shape.

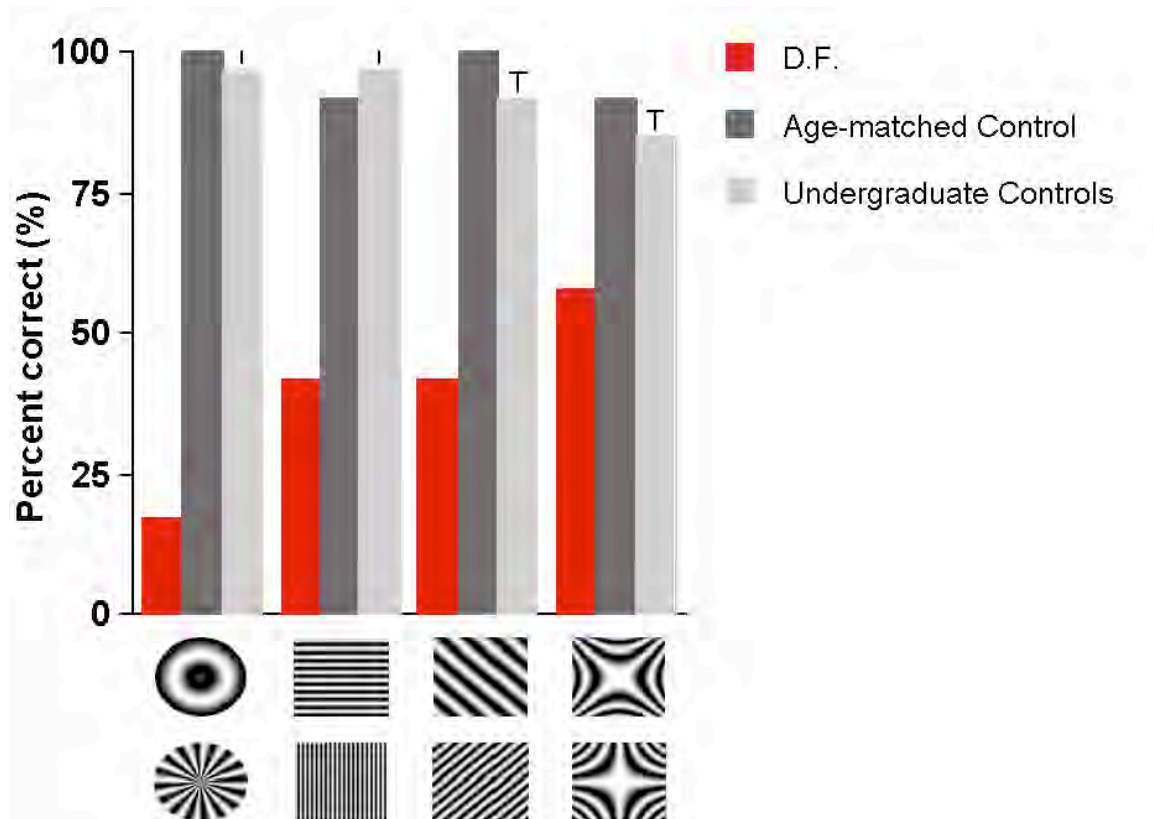


Figure 14. Percent correct performance in the match-to-sample shape discrimination task.

D.F.'s performance is near chance for all 4 categories.

### **Discussion:**

We find functional brain activation for face images in an area that is consistent with the fusiform face area (FFA) in both patient D.F. and neurologically-intact control subjects. This is a remarkable finding given that D.F. demonstrates severe prosopagnosia in addition to profound visual form agnosia. The FFA is commonly thought to be 'the'

face processing area, given that it has been implicated in several decades of reports of lesions in patients with prosopagnosia and has been activated in more recent functional imaging studies of neurologically-intact individuals when viewing faces. In the present paper, in addition to reporting face-selective activation in the FFA, we have also performed extensive behavioural tests in the same patient. D.F. can discriminate a face from an object or a non-face, but cannot perform higher-level face tasks including recognition of identity, gender, or emotional expression. Her deficit is restricted to the aspects of higher-level face processing.

D.F. shows clearly intact and functional fusiform gyri bilaterally but destroyed occipital face areas bilaterally. The FFA activation appears to be of reasonable size and shows normal BOLD signal change in both hemispheres. The presence of face-selective activation, however, is not necessarily evidence of normal function. It will be necessary to test this patient further for face-specific functional modulation of areas in the face network in order to address the functional integrity of these remaining face-selective areas. Our control observers all demonstrate OFA activation for faces, but patient D.F. does not show activation in either hemisphere in an area consistent with the OFA. It is possible that the small areas of activation nearby but not overlapping with the OFA of our controls could represent remapping of OFA activation or recruitment of other brain regions for face-selectivity. Taken together, our behavioural and imaging data from this patient suggest that it is likely that a fully intact complex face network including undamaged connections with the OFA are necessary to drive higher-level face processing.

How do our findings compare to those of others who have measured functional activation for faces in patients with prosopagnosia? On one hand, with respect to fusiform activation, this finding is relatively compatible with two recent studies, which have also shown FFA activation in patients with prosopagnosia. Rossion et al. (2003) show face-selective activation in the right fusiform gyrus in a patient with acquired prosopagnosia. Hasson et al. (2003) report that the activation for faces in their congenital prosopagnosia patient is normal with respect to the anatomical location, activation profiles and hemispheric laterality of the FFA in controls. On the other hand, two earlier studies by Marotta, Genovese and Behrmann (2001) and Hadjikhani and de Gelder (2002) report that the activation for faces in the fusiform gyrus in their patients with acquired and early prosopagnosia, respectively, is not normal compared to controls.

The cortical damage in one of Marotta et al. (2001) patients was right anterior and posterior temporal while in the other the damage was to the right temporal and medial occipital lobes and the right fusiform gyrus. These patients, however, exhibited more functional activation for faces in the anterior portion of the fusiform gyrus than did controls and one patient showed more left than right hemisphere activation. The authors did not test for OFA activity in their study, however. The stereotaxic coordinates of the locus of face-selective fusiform activation in one of their patients in particular, were altogether more anterior than those of their controls, which may account for the overall more anterior activation in the fusiform gyrus. Similarly, Hadjikhani and de Gelder (2002) did not find normal face-selective activation in the FFA nor the inferior occipital gyrus (IOG) in their patients with developmental or childhood prosopagnosia but they did find some relatively normal activation in object-selective areas during object viewing.

Their subjects performed just below normal on the Benton and Warrington face recognition tests but exhibited no evident lesions on the MR scan.

In the present study, however, we find the anatomical location of face-selective fusiform activation in D.F. to be consistent with those of our control observers and further, that these coordinates are similar to those seen in normal observers by others (e.g. Kanwisher, McDermott & Chun 1997; Epstein & Kanwisher, 1998). We also find OFA and STS activation in our controls, as do earlier studies of face-selective activation (e.g. Kanwisher et al., 1997; McCarthy et al., 1997; Puce et al., 1995) Patient D.F. also shows STS activation, but no OFA activation consistent with that of our controls. This appears to be because her lateral occipital lesions in both hemispheres overlap with the anatomical locus of the OFA. Hasson et al. (2003) studied a congenital prosopagnosic who was unable to recognize famous faces but who could recognize face gender, age and emotional expression. As is often the case with congenital cases, no evident structural lesion was revealed on MR scan. Their patient showed activation in areas consistent with the FFA and the OFA within the lateral occipital area. Talairach coordinates for these areas are comparable to those of our controls. But, the interesting result in the Hasson et al. (2003) study, is that there were subtle differences in selectivity for faces in the left from the right OFA of their patient. Given our findings, these differences could account for this patient's inability to recognize known faces despite preserved processing of other higher-level face attributes including recognition of gender, age and emotional expression. This is consistent with our supposition that a functionally intact complex face network including undamaged connections with the OFA is indeed more important than suspected for such higher-level face processing.

Rossion et al. (2003) tested a patient with left middle fusiform damage and right inferior occipital damage (presumably including the right OFA) but an intact right middle fusiform gyrus and left OFA. Behaviorally, although impaired compared to their control subjects on tests of face recognition, their patient still performed well above chance on tests of gender decision and recognition of emotional expression and was normal in her ability to assess the age of faces. Their patient showed left inferior occipital cortex responses for faces, which likely corresponds to the OFA, in an area posterior to the damaged area in one of the two scanning sessions. Given that both Hasson et al. (2003) and Rossion et al. (2003) found some face-selective activation, although abnormal, in the OFA *and* that their two patients have some residual higher-level face processing abilities including recognition of gender, age and emotional expression it seems likely that the OFA or its interconnections are partially damaged in these patients but those that remain are adequate to help drive these residual higher-level face processes. An earlier PET study by Sergent, Ohta and MacDonald (1992) also implicates the OFA in aspects of higher-level face processing. Specifically, they found activation changes in right extrastriate cortex for gender recognition and additional bilateral activation of the fusiform gyrus for a face recognition task. The data from patient D.F. show that she has no activation in an area consistent with the OFA in either hemisphere *and* no higher-level face processing abilities. It is highly likely that face recognition involves a complex face network requiring intact connections with the OFA area for face processing beyond basic face categorization. Again, further research is needed to determine whether D.F.'s face-selective activation in the fusiform revealed by a localizer is indicative of normal

functionality and also whether she shows remapping of the OFA in areas outside of that of our controls.

How capable is D.F. at face categorization? To summarize the behavioral data: D.F. can differentiate faces from non-faces given sufficient texture information and processing time, and this is independent of color and illumination information. She can use configural information when presented in an upright but not sideways orientation and given that she also cannot discriminate half-faces she may rely on a spatially symmetric feature arrangement. Moreover, faces appear to be a unique category, which she can classify even when she has no advance knowledge that she will be shown face images. D.F. cannot make any higher-level discriminations requiring recognition of known faces, emotion, or gender. In short, D.F. is a unique patient demonstrating a severe impairment in all aspects of higher-level face processing but relatively spared face categorization.

It is possible that D.F. is able to categorize internally symmetrical stimuli as faces without actually *seeing* them as faces. However, a large number of object images from which she discriminated faces were also spatially symmetric. Given her good performance on basic shape discrimination but poor performance on pattern discrimination when contained within similar global shapes, it is possible that patient D.F. initially uses differences in global shape to help her distinguish faces from other objects. It would be useful in future research to test D.F.'s ability to discriminate faces from other non-face stimuli with similar internal symmetry and also faces from other non-face stimuli with similar global shape, such as flowers or round fruit. In addition, it would be worthwhile to test functional activation in the face-processing network with symmetrical versus non-symmetrical shapes as well as images with similar and different

global shape in order to address the role of different components of this network in basic configural processing in D.F.

Several imaging studies in neurologically-intact humans have made the case that the FFA is involved in face categorization but not necessarily higher-level face recognition. For instance, Kanwisher, Tong and Nakayama (1998) also demonstrated that face discrimination is better for upright than inverted grayscale faces but activation in the FFA is only slightly lower for the latter condition. Haxby et al., (1999) demonstrated similar findings—inverted faces do not selectively diminish the response to faces in face-selective regions. Tong et al., (2000) demonstrated that the FFA responds well to human, animal and cartoon faces but responds less to schematic faces or facial features alone. It seems likely that configural face information is processed in the FFA since patients with right fusiform face area damage show deficits in configural processing (Barton et al., 2002). These findings suggest that the FFA plays a role in conscious detection of a face possibly by representing the local features and global configuration of a face.

Configural information may nonetheless be used to identify individual faces. Gauthier et al., (2000) showed that when subjects attend to the location of faces rather than identity, activity in the FFA and OFA is higher for presentations of different faces than presentation of the same face repeatedly. They argue that the FFA is involved in specific individual-level face processing. It is likely the case that the FFA does indeed process information that is ultimately necessary for individual-level face recognition such as face configuration and feature arrangement. Patient D.F. does appear to use spatially symmetric configural information for face categorization and shows FFA activation for faces. However, our data suggest that it is likely that an intact complex network is



necessary for this same configural information to be used for higher-level recognition tasks, such as identity and expression. Rossion et al., (2003) make a similar argument that the face-selective activation in the earlier visual area, the OFA, could result from feedback connections from the FFA to the OFA. The FFA may process higher-level face-sensitive information that is ultimately used for fine-grained visual analysis of faces at the individual level through feedback connections to the OFA.

As a final point, one should certainly exercise caution when interpreting data from single-patient studies given individual variability with respect to lesions and behavioral performance. Further, the site of a lesion does not necessarily correspond to the locus of the area responsible for perceptual/cognitive processing which is disrupted but could instead correspond to an interruption in the pathways to other areas where such processing is accomplished. When interpreting data from the present case of patient D.F., one must bear in mind that she does have profound agnosia of the apperceptive type, affecting more than just higher-level face processing. Nonetheless, these data in conjunction with those from other neuropsychological patients [i.e. Rossion et al., 2003; Hasson et al., 2003] contribute to a clearer picture of necessity of an intact complex face network in face processing. Patient D.F. has undamaged and functionally active FFAs but destroyed OFAs in both hemispheres and she also demonstrates a clear behavioral deficit in *all* aspects of face processing beyond categorization. These data lend strong support to the importance of the integrity of a complex network of regions for face identification, including more than just the FFA—in particular the OFA, a region believed to be associated with low-level processing.

## **Acknowledgements**

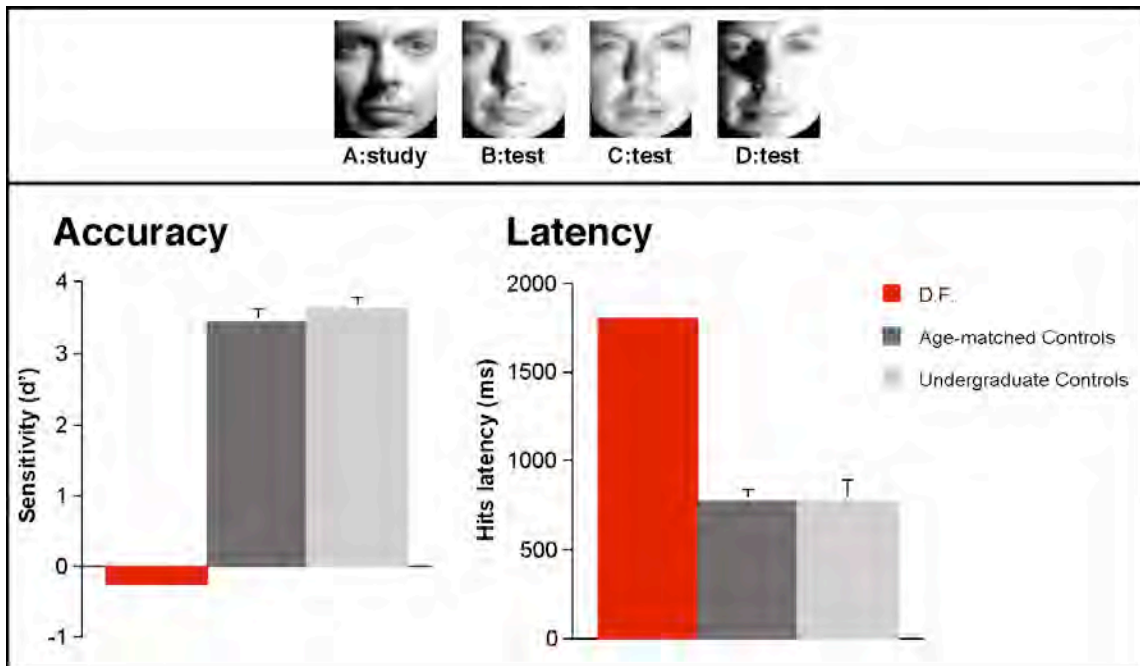
Foremost, we thank patient D.F. for her patience and continued willingness to participate in our experiments. We thank many people who helped provide test images: Paul Downing generously gave us line drawings of body parts, Frank Tong kindly sent us Mooney face images, some images were provided courtesy of Mike Tarr, and Tzvika Ganel generously gave us faces for the colored face categorization test. Faces for the face-matching and emotion recognition tasks were from the Psychological Image Collection at Stirling (PICS), Psychology Department, University of Stirling. We thank Jennifer Rycroft for collecting some of the control data.

## Supplemental Information

### *Higher-level face processing: Face recognition*

#### Face matching across different illumination

Conventional neuropsychological tests of face recognition such as Benton's Facial Recognition Test (Benton et al., 1983) can allow feature matching from one photo to another in the test array rather than matching overall facial configurations (Duchaine et al., 2003; Duchaine & Nakayama, 2004). This test attempted to reduce the use of feature matching strategies by not presenting target and test stimuli simultaneously but rather by requiring the subject to recognize 15 different photographs of a target individual, which differ in illumination, out of 150 photographs presented in succession (from Duchaine, 2000). See top panel Figure 1S for example images of the same face under different directions of illumination. Initially, the subject studied three grayscale photographs of the target individual that were cycled three times for three seconds each. In the test phase, the subject viewed each of the 150 test faces and was asked to indicate as quickly as possible whether or not the photograph was of the target individual. The face image remained on the screen until the subject responded. D.F. was significantly poorer at discriminating between target and distractor faces than control subjects. Her false alarm rate was again higher than her hit rate. Results are shown in Figure 1S. Again, D.F.'s response latencies were considerably slower than those for the control observers.



**Figure 1S.** In the top panel, A shows an example of a face learned during the study phase and B through D show that same individual under different illumination in the test phase. Accuracy and latency performance for D.F. and controls are shown below.

#### Face matching—frontal to 3/4 profile

In a match-to-sample design, subjects were shown a frontal view of a face in grayscale for 3 sec, which was followed immediately by three 3/4 profile photos, one of which was the same individual seen previously (from Duchaine, 2000). The subject was asked to indicate which of the three photos was the individual seen previously from a frontal view. A run consisted of 30 trials, fifteen of which contained adult male faces and fifteen contained adult female faces. Both undergraduate and age-matched controls averaged more than 90% correct face matching while D.F. performed just above chance. (Figure 2S).

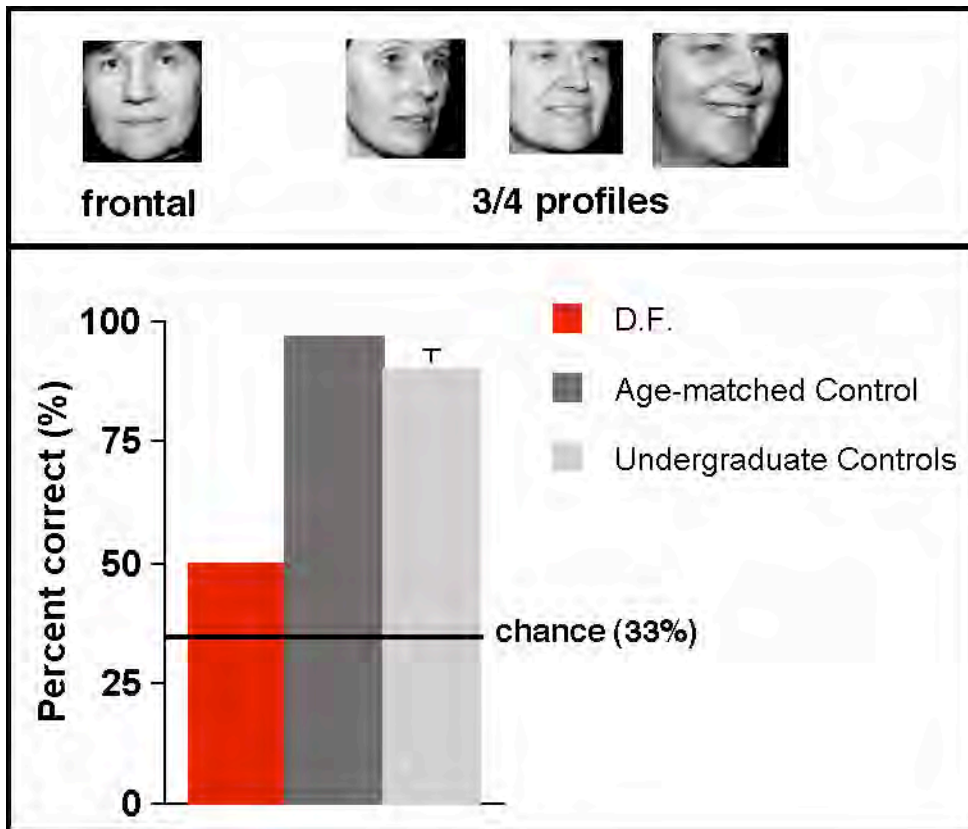


Figure 2S. The top panel shows an example of a frontal view of a face to be recognized in the adjacent three 3/4 profile faces. Performance accuracy is shown below.

## References

- Barton JJS, Press DZ, Keenan JP, O'Connor M. Lesions of the fusiform face area impair perception of facial configuration in prosopagnosia. *Neurology* 2002; 58: 71-18.
- Benton AL, Sivan AB, Hamsher K, Varney NR, Spreen O. (1983). *Contribution to Neuropsychological Assessment*. New York: Oxford University Press.
- Culham J. Neuroimaging investigations of visually-guided grasping. *Attention and Performance XX: Functional Brain Imaging of Human Cognition*. Oxford: Oxford University Press, 2004: 415-436.
- Damasio AR, Damasio H, Van Hoesen GW. Prosopagnosia: anatomic basis and behavioral mechanisms. *Neurology* 1982; 32: 331-341.
- Downing PE, Jiang Y, Shuman M, Kanwisher N. A cortical area selective for visual processing of the human body. *Science* 2001; 293: 2470-2473.
- Duchaine BC. Developmental prosopagnosia with normal configural processing. *Neuroreport* 2000; 11(1): 79-83.
- Duchaine BC, Nakayama K. (in press). Dissociations of face and object recognition in developmental prosopagnosic. *J Cog Neurosci*.
- Duchaine B, Nieminen-von Wendt T, New J, Kulomaki T. Dissociations of visual recognition in a developmental prosopagnosic: Evidence for separate developmental processes. *Neurocase* 2003; 9: 380-389.
- Duchaine B, Weidenfeld A. An evaluation of two commonly used tests of unfamiliar face recognition. *Neuropsychologia* 2003; 41: 713-720.
- Epstein R, Kanwisher N. A cortical representation of the local visual environment.

Nature 1998; 392: 598-601.

Epstein R, DeYoe EA, Press DZ, Rosen AC, Kanwisher N. Neuropsychological evidence for a topographical learning mechanism in parahippocampal cortex. *Cog Neuropsych* 2001; 18(6): 481-508.

Farah, M.H. (1990). *Visual Agnosia: Disorders of Object Recognition and What They Tell Us About Normal Vision*. Cambridge (MA): MIT Press.

Gauthier I, Tarr MJ, Moylan J, Skudlarski P, Gore JC, Anderson WA. The fusiform "face area" is part of a network that processes faces at the individual level. *J Cog Neurosci* 2000; 12(3): 495-504.

Grill-Spector, K. Knouf, N., Kanwisher, N. The fusiform face area subserves face perception, not generic within-category identification. *Nat Neurosci*. 2004; 7(5):555-562.

Grill-Spector K, Kourtzi Z, Kanwisher N. The lateral occipital complex and its role in object recognition. *Vision Res* 2001; 41: 1409-1422.

Hadjikhani N, de Gelder B. Neural basis of prosopagnosia: an fMRI study. *Hum Brain Mapp* 2002; 16: 176-182.

Halgren E, Dale AM, Sereno MI, Tootell RBH, Marinkovic K, Rosen BR. Location of human face-selective cortex with respect to retinotopic areas. *Hum Brain Mapp* 1999; 7: 29-37.

Haxby JV, Ungerleider LG, Clark VP, Schouten JL, Hoffman EA, Martin A. The effect of face inversion on activity in human neural systems for face and object perception. *Neuron* 1999; 22: 189-199.

Hasson U, Avidan G, Deouell LY, Bentin S, Malach,R. Face-selective activation in a congenital prosopagnosic subject. *J Cog Neurosci* 2003; 15(3): 419-431.

- Humphrey GK, Goodale MA, Jakobson LS, Servos P. The role of surface information in object recognition: studies of a visual form agnostic and normal subjects. *Perception* 1994; 23: 1457-1481.
- Humphreys G, Rumiati RI, Agnosia without prosopagnosia or alexia: Evidence for stored visual memories specific to objects. *Cog Neuropsych* 1998; 15: 243-277.
- James, T.W., Culham , J.C. Humphrey, G. K., Milner, A. D., & Goodale, M. A. (2003). Ventral occipital lesions impair object recognition but not object-directed grasping: A fMRI study. *Brain* 2003; 126: 2463-2475.
- Kanwisher N, McDermott J, Chun MM. The fusiform face area: a module in human extrastriate cortex specialized for face perception. *J Neurosci* 1997; 17: 4302-4311.
- Kanwisher N, Tong F, Nakayama K. The effect of face inversion on the human fusiform face area. *Cognition* 1998; 68(1): 1-11.
- Li FF, VanRullen R, Koch C, Perona P. Rapid natural scene categorization in the near absence of attention. *Proc Natl Acad Sci* 2002; 99(14): 9596-601.
- Malach R, Reppas, JB, Benson RR, Kwong KK, Jiang H, Kennedy WA, Ledden PJ, Brady TJ, Rosen BR, Tootell BH. Object-related activity revealed by functional magnetic resonance imaging in human occipital cortex. *Proc Natl Acad Sci* 1995; 92: 8135-8139.
- Marotta JJ, Genovese CR, Behrmann M. A functional MRI study of face recognition in patients with prosopagnosia. *NeuroReport* 2001; 12: 1581-1587.
- McMullen P, Fisk JD, Phillips S. Apperceptive agnosia and face recognition. *Neurocase* 2000; 6: 403-414.
- McNeil JE, Warrington EK. Prosopagnosia: a face-specific disorder. *Q J Exp Psychol*



1993; 46A: 1-10.

Milner AD, Heywood CA. A disorder of lightness discrimination in a case of visual form agnosia. *Cortex* 1989; 25: 489-494.

Milner AD, Perrett DI, Johnston RS, Benson PJ, Jordan, TR, Heeley DW, Bettucci D, Mortara F, Mutani R, Terassi E, Davidson DL. Perception and action in 'visual form agnosia'. *Brain* 1991; 114: 405-428.

Mooney, CM. Closure with negative after images under filtering light. *Can J Psychol* 1956; 10:191-199.

Moscovitch M, Winocur G, Behrmann M. What is special about face recognition? Nineteen experiments on a person with visual object agnosia and dyslexia but normal face recognition. *J Cog Neurosci* 1997; 9: 555-604.

Nunn, JA, Postma P, Pearson R. Developmental prosopagnosia: should it be taken at face value? *Neurocase* 2001; 7:15-27.

Pallis, CA. Impaired identification of faces and places with agnosia for colours; report of a case due to cerebral embolism. *J Neurochem* 1955;18(3): 218-24.

Puce A, Allison T, Asgari M, Gore JC, McCarthy G. Differential sensitivity of human visual cortex to faces, letterstrings, and textures: a functional magnetic resonance imaging study. *J Neurosci* 1996;16(6): 5205-5215.

Rossion B, Caldara R, Seghier M, Schuller, A-M, Lazeyras F, Mayer E. A network of occipito-temporal face-sensitive areas besides the right middle fusiform gyrus is necessary for normal face processing. *Brain* 2003; 126: 2381-2395.

Sergent J, Ohta S, MacDonald B. Functional neuroanatomy of face and object processing. A positron emission tomography study. *Brain* 1992; 115: 15-36.

- Sprengelmeyer R, Young AW, Calder AJ, Karnat A, Lange H, Homborg V, Perrett DI, Rowland D. Loss of disgust. Perception of faces and emotions in Huntington's disease. *Brain*. 1996;119:1647-1665.
- Steeves JKE, Humphrey GK, Culham JC, Menon RS, Milner AD, Goodale MA. Behavioral and neuroimaging evidence for a contribution of color and texture information to scene classification in a patient with visual form agnosia. *J Cog Neurosci* 2004; 16:6.
- Talairach J, Tournoux P. (1988). Co-planar stereotaxic atlas of the human brain. New York: Thieme Medical Publishers.
- Tanaka JW, Farah MJ. Parts and wholes in face recognition. *Quarterly Journal of Experimental Psychology A* 1993; 46(2): 225-45
- Vaina LM, Solomon J, Chowdhury S, Sinha P. & Belliveau. Functional neuroanatomy of biological motion perception in humans. *Proc Natl Acad Sci* 2002; 98:11656-11661.
- Whiteley AM, Warrington EK. Prosopagnosia: a clinical, psychological, and anatomical study of three patients. *J Neurol Neurosurg & Psych* 1977; 40(4): 395-403
- Wilkinson F, James TW, Wilson HR, Gati, JS, Menon, RS, & Goodale MA. An fMRI study of the selective activation of human extrastriate form vision areas by radial and concentric gratings. *Current Bio* 2000; 16: 1455-8.
- Yin RK. Looking at upside-down faces. *J Exp Psychol* 1969; 81:141-145.