

**Impaired grasping in a patient with optic ataxia: Primary
visuomotor deficit or secondary consequence of misreaching?**

*Cristiana Cavina-Pratesi¹, Magdalena Ietswaart², Glyn W. Humphreys³, Vaia
Lestou³, A. David Milner¹*

¹Department of Psychology, Durham University
Science Laboratories, South Road, Durham DH1 3LE, UK

²School of Psychology and Sport Sciences, Northumbria University
Newcastle-upon-Tyne NE1 8ST, UK.

³Behavioural Brain Sciences, School of Psychology, University of Birmingham
Birmingham, B15 2TT, UK

Running title: Impaired grasping in a patient with optic ataxia

Abstract: 249 words

Main text: 5786 words (without references)

Figures: 6 (2 in colour)

Address for correspondence:

Dr C Cavina-Pratesi
Department of Psychology, Durham University
Science Laboratories, South Road, Durham UK - DH1 3LE
Phone +44-191-334-3258
Fax +44-191-334-3241
Email cristiana.cavina-pratesi@durham.ac.uk

Acknowledgements

The authors are grateful to Dr Robert McIntosh and Dr Thomas Schenk for their comments on the first draft of the manuscript and to Isabella Curti for helping during data collection. Most of all, the authors wish to thank M.H for his kindness and endless patience. The research was funded by the Medical Research Council (grant no. G0401090).

Abstract

Optic ataxia is defined as a spatial impairment of visually guided reaching, but it is typically accompanied by other visuomotor difficulties, notably a failure to scale the handgrip appropriately while reaching to grasp an object. This impaired grasping might reflect a primary visuomotor deficit, or it might be a secondary effect arising from the spatial uncertainty associated with poor reaching. To distinguish between these possibilities, we used a new paradigm to tease apart the proximal and distal components of prehension movements. In the “far” condition objects were placed 30 cm from the hand so that subjects had to make a reaching movement to grasp them, whereas in the “close” condition objects were placed adjacent to the hand, thereby removing the need for a reaching movement. Stimulus eccentricity was held constant. We tested a patient with optic ataxia (M.H.), whose misreaching affects only his right hand within the right visual hemifield. M.H. showed a clear impairment in grip scaling, but only when using his right hand to grasp objects in the right visual hemifield. Critically, this grip-scaling impairment was absent M.H. in the “close” condition. These data suggest that M.H.’s grip scaling is impaired as a secondary consequence of making inaccurate reaching movements, and not because of any intrinsic visuomotor impairment of grasping. We suggest that primary misgrasping is not a core symptom of the optic ataxia syndrome, and that patients will show a primary deficit only when their lesion extends anteriorly within the intraparietal sulcus to include area aIPS.

Keywords: Grip, Reaching, Optic ataxia, Humans, Single case

Introduction

In a pioneering series of studies, Jeannerod (1984, 1988) proposed that reach-to-grasp actions, such as picking up a desired object, can be partitioned into distinct and quasi-independent visuomotor parts. He argued that the action of moving the arm to bring the hand to the target object (the “proximal” or “transport” component) is principally influenced by visual information signaling the location of the object, whereas the concurrent anticipatory pre-shaping of the hand and fingers in readiness for the grasp (the so-called “distal” or “grip” component) is guided principally by the geometric properties of the object. Although it is accepted that the two components must be somehow mutually co-ordinated, there is now extensive evidence that the transport component and the grip component are each controlled on-line by dedicated visuomotor networks within the posterior parietal cortex, in association with linked systems in the premotor cortex (Castiello, 2005; Castiello & Begliomini, 2008; Jeannerod et al., 1995; Milner & Goodale, 2006; Tanné-Gariépy et al., 2002).

It has long been known that both components of prehension can be severely disrupted by lesions of the posterior parietal cortex. Damage to this region (particularly around the intraparietal sulcus) in humans is associated with optic ataxia (Perenin & Vighetto, 1988; Karnath & Perenin, 2005), classically defined as a deficit in accurate reaching for visual targets (Bálint 1909; Harvey 1995). In the great majority of patients with optic ataxia, grasping turns out to be impaired as well as reaching, and indeed patients will typically fumble for the target with the fingers widely spread, whatever the size of the target (Jeannerod 1986; Perenin & Vighetto, 1988, Jakobson et al., 1994). This stands in sharp contrast to the normal pattern in which the handgrip opens only so far as to exceed the target size by a safe margin, and then smoothly closes in (Jeannerod, 1984; Jakobson & Goodale, 1990). Such distal

impairments have been associated with optic ataxia since the earliest reports of misreaching following parietal damage, in both monkeys and humans (Ferrier, 1886, 1890; Lamotte & Acuna, 1978; Faugier-Grimaud *et al.*, 1978; Damasio & Benton, 1979; Jeannerod, 1986; Perenin & Vighetto, 1988). Indeed this close association between the distal and proximal deficits led Perenin and Vighetto (1983, 1988) to follow Bálint (1909) in arguing that optic ataxia reflects a general impairment of visuomotor control rather than a deficit in visuospatial perception (as proposed by Holmes, 1918).

There is of course no necessary contradiction between this neuropsychological association between the distal and proximal deficits, and the quasi-modular visuomotor organization in the brain proposed by Jeannerod and his colleagues. It is entirely reasonable to argue that in most of the patients (and monkeys) studied, the lesions were extensive enough to have compromised both the “grasping” and the “reaching” visuomotor modules. None the less, the question does still arise as to whether an impairment in grip scaling necessarily implies that the patient has damage to such a “grasping” module. Instead, optic ataxia, by virtue of causing inaccurate reaching, might inevitably result in a maximally wide handgrip, simply in order to reduce the margin of error when the patient is trying to grasp an object.

Such an idea would not of course contradict the fact that some patients with parietal lesions mis-grasp without misreaching (Jeannerod *et al.*, 1994; Binkofski *et al.*, 1998). These patients, who would not be considered to have optic ataxia, tend to have lesions that include anterior parts of the intraparietal sulcus, in particular the “grasp” region known as AIP or aIPS (Binkofski *et al.*, 1998). These findings are important, because they refute the argument that mis-grasping might *always* be a secondary side-effect of misreaching. The data also mesh nicely with research using

functional MRI which has demonstrated distinct activation patterns for grasping (Binkofsky et al., 1999; Culham et al., 2003; Frey et al., 2005; Cavina-Pratesi et al., 2007), separate from those for reaching (Connolly et al., 2003; Astafiev et al., 2003; Prado et al., 2005, Culham et al., 2008). Complementary evidence also comes from nonhuman primate studies finding a clear double dissociation between proximal/arm and distal/hand errors following localized microinjections of muscimol (Gallese et al., 1994).

Although misgrasping can clearly arise in the absence of misreaching, it remains uncertain that the converse dissociation holds true in patients with optic ataxia. That is, it remains possible that in many such patients impaired grasping arises purely as a secondary consequence of misreaching, and not as the result of disruption of the “grasp” module.

Flesh can be put on the bones of these doubts. Numerous visuomotor studies show a tendency in healthy subjects to increase the size of their anticipatory grip aperture to compensate for factors that increase transport inaccuracy during reaching toward the object to be grasped. In one such study, maximum grip aperture (MGA) was found to be significantly greater during reaching movements that were performed faster than normal, and also during reaching with the eyes closed (Wing et al., 1986). In both cases, this wider hand aperture was accompanied by less accurate transport of the hand toward the target location. It is reasonable to infer that in these circumstances anticipatory grip aperture was enlarged to give a wider margin of error for achieving a successful capture of the object, thereby compensating for the spatial inaccuracy associated with speeded movements. Similar findings of an increased maximum grip aperture during reaching have been reported in cases where the stimulus uncertainty is increased in other ways, for example when visual target size is reduced (Berthier et al

1996), when the field of view is restricted (González-Alvarez et al., 2007), or when the target eccentricity is increased (Goodale & Murphy, 1997; Schlicht & Schrater, 2007).

In the present paper we aimed to test whether deficits in grip calibration can be separated from deficits in reaching accuracy in optic ataxia, by the use of a task requiring grasping without arm transport. Such a task was developed by Cavina-Pratesi et al. (2006; see also Culham et al., 2008) in order to achieve a clean contrast between ‘pure grasping’ and ‘pure reaching’ in a functional MRI study¹. We adopted this methodology in the present experiment in an attempt to tease apart the transport from the grasp impairment in a patient with optic ataxia (M.H.). Our specific intention was to establish whether his grasping difficulties were primary, or secondary to poor reaching; but at the same time we wished to validate our method so that it might be used for making unambiguous assessments of other such patients in the future.

Methods

Subjects

Patient M.H. had suffered an anoxic episode 8 years prior to the current testing. Structural MRI carried out in 2006 revealed disseminated damage in posterior parietal and frontal regions, concentrated particularly in the vicinity of the intra-parietal sulcus of the left hemisphere, with some extension onto the medial aspect and into the inferior parietal lobule. Some atrophy was visible in the left hemisphere both cortically (within the posterior parietal, fronto-temporal and frontal regions) and subcortically (lentiform nucleus and claustrum). The occipital lobes were largely unaffected. The anoxic incident that caused his brain injury resulted in right side

¹ Notably, a similar method was devised by Schenk et al. (2003), for use in a different context.

muscle weakness and raised sensory thresholds. He was still able to walk and use both hands, though he reported difficulties in everyday living activities, such as dressing, eating with a knife and fork, and writing. Clinical assessment exhibited symptoms of contralateral optic ataxia, most clearly when using his right hand, and when reaching toward targets in right hemispace under condition of central visual fixation (Rice et al., 2008). M.H also showed impairments in spatial perception (Riddoch et al., 2004), though clinical assessment showed no evidence of unilateral spatial neglect or agraphia.

Somatosensory performance was assessed using the Rivermead Assessment tests (Winward, Halligan & Wade, 2000). MH scored at ceiling when discriminating surface pressure on both his hands and face (control level); he also detected all bimanual and unimanual stimuli in the Rivermead test of sensory extinction applied both to the face and the hands (tests 2 and 4). His two-point discrimination on each hand was 4mm (test 5), again within the control range. MH had a grating resolution threshold of 2mm (fair, relative to a group of older controls, in Manning & Tremblay, 2006), for both hands, on a task requiring him to decide whether a grating went along or across his finger (the threshold = minimum width to make 75% discriminations). MH was also able to discriminate the 2.83 filament (normal) on his ipsi- and contralesional fingers on the Semmes-Weinstein monofilament test (Bell, 1984). These data indicate that there was no major somatosensory loss in either hand. M.H. was aged 50 at the time of testing.

In addition to patient M.H., 7 age-matched neurologically intact controls were tested (all male; mean age 52.1, range 45 to 61). Since M.H. has essentially no reaching deficit when using his left hand, or towards targets in the left visual field (confirmed in the Results below), M.H. also served as his own control.

The ethics committees of the University of Birmingham School of Psychology and Durham University Department of Psychology approved the experiments described here, and informed consent was obtained prior to the study in accordance with the principles of the Declaration of Helsinki.

Procedure

Subjects sat comfortably in front of a 50 x 50 cm board laid horizontally on a table. As shown in Figure 1, there were four possible locations where a target object could be placed: two near and two distant from the participant, 30 cm apart on left and right, and forming a square arrangement such that the near locations were 30 cm from the distant locations. A fixation point (a flashing red LED) was located at the centre of the square. At the beginning of each trial, as indicated in Figure 1, the subject's left or right hand was placed adjacent to one of the potential object locations on a given side of the board (on the right side of the location when using the right hand and on the left side of the location when using the left hand). The starting position of the hand was specified by the use of a small plastic disc (white dot in Figure 1) fixed to the board, at which the subject placed their pinched forefinger and thumb at the start of each trial. The object was then placed on the same side of the board, either close to the hand or far from the hand. Placing the object at the location adjacent to the hand enabled subjects to grasp the object without making an arm movement (hereafter referred to as the "close" condition). Placing the object at the other location, however, required the subject to move his or her arm towards the object in order to complete the grasp ("far" condition).

According to the starting position used, the reaching movement would thus be performed either by the use of an outward or an inward movement (see Figure 1).

When the hand starting position was located near to the body, the movements would be directed outwards, away from the body. Conversely, when the starting position was located distant from the body, the reach would be directed inwards, towards the body. The use of both outward and inward reaches ensured that the retinal location of the target object (in either the upper or lower visual hemifield) was balanced across both close and far prehension conditions.

Two different objects were used, both of which were rectangular blocks made from 1-cm-thick black plastic. The two blocks had an identical top surface area, but one was a 5-cm square whereas the other was a 3 cm x 8.3 cm oblong, placed with the long axis in the fronto-parallel plane. Since subjects were asked to grasp the objects front-to-back, the oblong block was designated the “small” object and the square the “large” object. The objects were located by means of specific signs on the experimental board visible only to the experimenter, allowing a precise positioning of the stimuli relative to the hand on every trial. Liquid crystal shutter glasses (*Plato System*, Translucent Technologies, Toronto, Canada) were used in order to control viewing time of the array.

[Figure 1 about here]

Data were collected from the control subjects in two separate sessions (one for each hand). Within each session there were 8 blocks of trials: one for each combination of stimulus side (left vs right), viewing condition (free viewing vs central fixation) and movement direction (outward vs inward). Within each block of trials, the target object (small vs large) and the proximity of the hand to the object (close vs far) were varied pseudo-randomly. Target hemispace and movement direction were counterbalanced within the free viewing and central fixation sequences using an ABBA design. Left/right hand use and central-fixation/free-viewing were balanced

across subjects. Patient M.H was also tested in two sessions. During session 1, M.H used his right hand while performing under conditions of both free viewing and fixation. During the second session, M.H. was tested with both his right hand and his left hand, but under central fixation conditions only, in order to avoid excessively long testing sessions. We thereby maximized data collection for the conditions of most interest, namely M.H.'s use of his right hand while maintaining fixation, given that the previous session had revealed no impairments during reaching under free viewing conditions (see Results below). In addition, during the second session we checked M.H.'s ability to discriminate visually between the two objects at all spatial locations while maintaining central fixation.

At the beginning of each trial the shutter glasses opened and after 2 s a tone instructed the participant to pick up the object and place it over the central fixation position. Movements were performed entirely in visual closed loop (that is, with full vision of the hand). M.H.'s fixation was monitored by a second experimenter on all trials. Movements were recorded by sampling the position of three markers (on thumb, index finger and wrist) at a frequency of 86.1 Hz, using an electromagnetic motion analysis system (*Minibird*, Ascension Technology Ltd). Each block was composed of 40 trials (10 for each object at each location – near and far).

Analysis of data

Data analysis was performed on the proximal (transport) component and the distal (grip) component separately.

We first assessed performance on the reach component by analysing movement Transport Error (TE, in mm) which was measured as the Cartesian distance (mean absolute distance, and variance of the absolute distance) between the landing position

of the wrist marker and the target position. We defined the landing position (X and Y coordinates) of the wrist as its location at the end of the ballistic part of the reach, since after this point M.H. would often grope for the object in order to pick it up. The end of the ballistic movement was calculated as the moment at which the velocity of the wrist marker fell below 50mm/s. Although the transport movement toward the close target was negligible, the small displacement of the wrist necessary to access the objects and grasp them was clearly captured by the wrist marker, and was analyzed using the same criteria as for the transport to the far object.

The grip component was analysed by measuring Maximum Grip Aperture (MGA), computed as the maximum distance in 3D space between index and thumb markers during the ballistic part of the movement. Other measures of transport (movement time, peak velocity and time to peak velocity) and grip (time to MGA) kinematics were also analyzed (and can be accessed by contacting the first author), but are not reported here because they are not relevant to the current experimental question.

The data from the controls and from patient M.H. were analyzed separately using ANOVA statistics in order to examine how the experimental manipulations affected the transport and the grip components within each group. Data from the controls were analyzed using repeated-measures ANOVAs where Viewing Condition (free vs fixation), Hand (left vs right), Space (left vs right), Movement direction (inward vs outward), Distance (close vs far) and Size (large vs small object) were used as within-subjects factors. Post-hoc analyses were performed by using corrected paired comparison t-tests, and reported wherever significant at $p < 0.05$. Data from patient M.H. were analyzed using two 5-way factorial ANOVAs. First we examined his performance with the right hand only, during the two different viewing conditions, using as factors: Viewing Condition (free vs fixation), Space (left vs right),

Movement direction (inward vs outward), Distance (close vs far) and Size (large vs small object). In the second analysis we tested M.H.'s performance during central fixation only, using both right and left hands, with the factors: Hand (left vs right), Space (left vs right), Movement direction (inward vs outward), Distance (close and far) and Size (large and small object).

Finally, we adopted the modified t-test recommended by Crawford and Garthwaite (2002, 2004), to assess whether M.H.'s performance was significantly different from the controls. In order to be concise we report here the significant results only.

Results

Neurologically intact participants

Transport component

Analysis of the mean reaching error (TE) revealed a significant interaction of Viewing Condition x Distance ($F_{(1,6)}=10.90$, $p=0.016$) with the mean TE for the far reaches being higher (9.82 mm) than for close ones (8.99 mm) during central fixation only. Analysis of the variability of TE showed a significant main effect of Movement direction ($F_{(1,6)}=11.96$, $p=0.014$) with inward movements (22.4) being less variable than outward (27.6) ones. In addition, an interaction of Hand x Space ($F_{(1,6)}=6.31$, $p=0.046$) showed that ipsilateral movements (left hand: 28.9, right hand: 27.2) resulted in higher variance (28.3) than contralateral ones (left hand: 24.8; right hand: 19.2).

Grip component

Analysis of MGA revealed significant main effects of Viewing Condition ($F_{(1,6)}=71.8$, $p=0.0001$; fixation: 99.2 mm; free viewing: 90.6 mm) and Size

($F_{(1,6)}=431.27$, $p=0.0001$; large object: 103.7 mm, small object: 86.7 mm). An interaction of Viewing Condition x Size ($F_{(1,6)}=13.5$, $p=0.01$) reflected a larger difference in MGA for large than for small objects during central fixation only (central fixation: large object=107.9 mm, small object=91.5; free viewing: large object= 99.5 mm and small object=81.7 mm).

Overall, these control data show that TE is greater and more variable under conditions of fixation and when the objects are located far from the start point, thereby requiring arm transport. Likewise, MGA (and its size scaling) was larger when the subjects were asked to fixate centrally. This may reflect greater spatial uncertainty for actions executed under these conditions, given previous reports that larger MGA is associated with increased transport error prior to contact (Wing et al., 1986).

Patient M.H.

Visual discrimination

At the beginning of session 2, we asked patient M.H. to visually identify the two objects at each of the four possible object locations while maintaining central fixation. The objects were presented following the same sequence as used for visuomotor testing, and the patient was asked to name each object immediately after the opening of the shutter glasses. M.H.'s overall accuracy was very high, with only 1 error (=95% accuracy) being made at each location within each hemifield.

Transport component

Figure 2 shows the landing position results for M.H. and for the age-matched control subject (I.D.) separately for inward and outward reaches. Analysis of M.H.'s reaching error (TE) was computed on a trial by trial basis, therefore ANOVAs could only be carried out on the mean TE scores. The variability of TE (calculated as the variance of the trial by trial TE scores and therefore represented by a single value for each experimental condition) was analysed only by the use of Crawford and Garthwaite's (2002) modified t-test.

[Insert figure 2 about here]

We first analyzed M.H.'s right hand performance alone, using Viewing Condition, Space, Movement Direction, Distance and Size as factors. We found main effects of Viewing Condition ($F_{(1,279)}=97.23$, $p=0.0001$), Space ($F_{(1,279)}=98.00$, $p=0.0001$). Movement direction ($F_{(1,279)}=15.30$, $p=0.0001$) and Distance ($F_{(1,279)}=67.50$, $p=0.007$). TE was greater under fixation conditions (free viewing=9.2 mm, fixation=20.7 mm); in right hemispace (left=9.3 mm, right=20.8); for outward reaches (inward reach=12.7 mm; outward =17.3 mm); and for far distances (close=10.2mm, far=19.8mm). Consistent with our expectations, a significant 3-way interaction of Viewing Condition x Space x Distance ($F_{(1,187)}=4.05$, $p=0.04$) was found, reflecting the fact that errors were greatest for actions while fixating centrally, made to far target objects within right hemispace (see Figure 2, red versus green diamonds, and Figure 3, black bars).

In a second factorial ANOVA, we analysed the fixation data only, using Hand, Space, Movement direction, Distance and Size as factors. We found main effects of Hand ($F_{(1,270)}=5.70$, $p=0.018$), Space ($F_{(1,270)}=93.98$, $p=0.0001$), Movement direction ($F_{(1,270)}=52.2$, $p=0.0001$), and Distance ($F_{(1,270)}=48.9$, $p=0.0001$). TE was greater for the right hand (left =11.7 mm, right =20.8 mm), within right hemispace (left =10.2

mm, right =22.3 mm), for outward movements (inward: 14.8 mm; outward: 17.7 mm), and for far reaches (close =11.9 mm, far =20.6 mm). Most importantly, there was a three-way interaction of Hand x Space x Distance ($F_{(1,270)}=54.7$, $p=0.0001$) reflecting the fact that TE was highest for far reaches, made with the right hand, within right hemispace (see Figure 2, red versus yellow diamonds and Figure 3, black bars). Lastly, a four-way interaction of Hand x Space x Reaching direction x Distance reached significance ($F_{(1,270)}=6.2$, $p=0.014$), reflecting the fact that the transport error for far-amplitude right-hand actions within right space was higher for outward than for inward reaches (see Figure 3, black bars).

[Insert figure 3 about here]

As shown in Figure 3, only M.H.'s far reaches, executed under central fixation and using his right hand, were found to be significantly different from the control group ($t=13.48$, $p=0.0001$ for the outward reaches and $t=4.68$, $p=0.003$ for the inward reaches, with an estimated 100% and 99.83% of the normal population falling below M.H.'s score, respectively). The same analysis was performed for the variance of TE (see Figure 4), and again we found a significant difference for M.H.'s actions when he made far reaches, with his right hand, within right space ($t=78.29$, $p=0.0001$ for outward reaches and $t=52.16$, $p=0.0001$ for inward reaches, both with an estimated 100 % of the normal population falling below M.H.'s score). Unlike his mean TE, M.H.'s variance of TE was significantly different from that of controls when he made close movements with his right hand in right space ($t=7.25$, $p=0.0001$ for outward reaches and $t=8.71$, $p=0.0001$ for inward reaches, both with an estimated 99.98% of the normal population falling below M.H.'s score). The amount of scatter around the reference point for such close actions – made with the right hand within right space during central fixation – did not however exceed the spatial variability expected from

the fact that participants can grasp objects using a range of different landing positions on the object. This spatial variability was computed graphically by using the largest value in length (8 cm) and depth (5 cm) of the two objects (Figure 4, dotted rectangles).

[Insert Figure 4 about here]

These results replicate previous findings showing that M.H.'s reaching impairment is confined to right-hand actions directed at objects in his right visual hemifield (Rice et al., 2008). Our data extend those previous results by showing that M.H.'s pattern of reaching impairment is just the same within a reach-to-grasp task as in a pointing task. In addition, our data show that M.H.'s impairment is present for inward as well as outward movements. It is however present – perhaps unsurprisingly – only when the action requires arm transport (i.e. when stimuli are presented far from the hand).

Grip component

Analysis of the MGA in M.H. was computed on a trial by trial basis. We first analyzed right-hand performance only, using Viewing Condition, Space, Movement direction, Distance and Size as main factors. We found main effects of Viewing Condition ($F_{(1,290)}=126.2$, $p=0.0001$), Space ($F_{(1,290)}=39.6$, $p=0.0001$), Movement direction ($F_{(1,290)}=6.4$, $p=0.012$), Distance ($F_{(1,290)}=9.9$, $p=0.02$) and Size ($F_{(1,290)}=279.3$, $p=0.0001$). MGA was wider for the larger object (large=99.6 mm, small=87.8 mm), during central fixation (fixation=97.6 mm, free viewing=89.8 mm), for stimuli in right space (right =95.9 mm, left =91.5 mm), for outward movements (inward=92.8 mm, outward= 94.6 mm), and for movements to objects far from the hand (far =94.8 mm, close =92.6 mm). Critically, the 4-way interaction of Viewing Condition x Space x Distance x Size ($F_{(1,290)}=5.5$, $p=0.02$) was also significant. This

reflects the fact that there was no difference in MGA for the large vs small objects, only when these were positioned far from the hand in right space, under conditions of fixation. This result is shown graphically in figure 5.

[Insert Figure 5 about here]

Next, we analysed the fixation data alone – so that the factor “Space” became equivalent to “visual hemifield” – in separate 4-way ANOVAs for each hand. For the right hand, all the main factors proved significant, as before. More importantly, the 3-way interaction of Space x Distance x Size now reached significance ($F_{(1,146)}=6.6$, $p=0.011$), reflecting again the lack of difference in MGA for large vs small objects when far reaches were executed within the right hemifield (Figure 5). As for the left hand, all the main effects except movement direction proved significant, and most importantly we did not find a 3-way interaction of Space x Distance x Size ($F_{(1,132)}=2.5$, $p=0.115$), confirming the fact that the lack of grip scaling for far reaches in the right hemifield was restricted to the right hand.

We then checked whether the patient’s grip calibration was different from that found in the controls, using Crawford and Garthwaite’s (2004) modified t-test. As illustrated in Figure 5 (middle panel), the slope of the function for far right-hand actions made towards targets in the right hemifield was significantly different from those seen in the controls ($t=-3.90$ $p=0.0018$, with an estimated 99% of the normal population falling above M.H.’s slope).

Discussion

Our aim in this study was to tease apart the reaching and grasping impairments in a patient with optic ataxia (M.H.), by varying the proximal and distal requirements of a prehensive action. We manipulated the proximal component (arm transport) by asking our participants to grasp objects either at a close location adjacent to the hand (arm transport not required), or at a far location within reach of the hand but not immediately adjacent to it (arm transport required). We manipulated the distal component (grip aperture) by having participants grasp objects of two different widths.

M.H. showed a reaching impairment (larger errors in both X and Y coordinates) when reaching to grasp objects using his right hand within right hemispace, under conditions of central fixation. In contrast he performed at a level of accuracy comparable to the controls when using his right hand within the left space, and when using his left hand within either side of space, under the same fixation conditions. No misreaching was apparent when M.H. was allowed to view the stimulus freely and thus fixate it directly – in other words his misreaching was truly restricted to the right hand within the right visual hemifield (i.e. the right side of space when fixating centrally). These reaching errors were, for obvious reasons, most prominent in the ‘far’ condition, where arm transport was required. M.H.’s pattern of specific contralateral deficits related to the right hand and the right hemifield is fully consistent with previous reaching data (Rice et al., 2008). We further extended those previous observations by finding that M.H. showed an identical pattern of contralateral inaccuracy, albeit less pronounced, when his movements were made inwards, towards the body, rather than outwards.

We also found, as perhaps might be expected from the previous literature on optic ataxia caused by unilateral lesions (Perenin & Vighetto, 1988; Rice et al., 2008), that M.H.'s deficit in anticipatory hand shaping was closely coupled with his reaching errors. That is, his grasping was poorly scaled under exactly those conditions where he made reaching errors, namely when he executed right-handed actions toward far objects in the right hemispace while fixating centrally. His handgrip was scaled well to object width in all of the other conditions; for example M.H.'s grip scaling was always normal when using his left hand, and always when free viewing was allowed. Perceptual testing was carried out to exclude the possibility that any lack of scaling seen during the experiment was due to a peripheral visual impairment *per se*: when asked verbally, M.H. proved able to distinguish the two objects accurately at all locations. Although this perceptual task was very basic (assigning two objects between two categories), it was deemed sufficient to confirm the absence of any gross visual deficit that might interfere with correct hand shaping while grasping in the periphery. If the results of the lack of scaling during misreaching were due to a compensatory enlargement of safety margins during grasping in order to overcome any degraded visual information in the periphery, then it is unclear why M.H. did not apply the same strategy when asked to grasp the same objects when located close. Furthermore, Figure 5 demonstrates that MGA for close objects within the impaired right hemifield did not vary between central fixation and free viewing. Finally, of course, the fact that there was no visuomotor deficit in this same retinal location when M.H. used his left hand also provides strong internal evidence against any peripheral visual loss.

Our critical finding was that under our 'close' conditions, M.H.'s right-handed grasps toward objects in the right hemifield were well scaled. This spared grasp

calibration could not have been due to the target object having been located in a different part of the visual field for close and far testing. Our fully balanced design, incorporating both inward and outward reaches, meant that the targets of close and far actions were matched for visual location across the experiment.

If the grip component of reaching-to-grasp movements were impaired in M.H. as a primary visuomotor deficit, then it should have been impaired regardless of the presence or amplitude of the transport component. That is, M.H. should have shown equally poor grip scaling in both the “close” and “far” conditions of testing. Such an outcome would be expected, for example, if his brain damage extended to include the anterior portion of the intraparietal sulcus (aIPS), which is known from functional neuroimaging studies to be strongly activated during object grasping movements (Binkofski et al., 1999; Culham et al., 2003; Frey et al., 2005; Cavina-Pratesi et al., 2007), even when no reaching movement is required (Cavina-Pratesi et al., 2006). Instead, our evidence indicates that M.H.’s grasping impairment (i.e. his failure to scale his grip, and his tendency to grope for the object) is secondary to his reaching impairment. Presumably M.H., wittingly or unwittingly, compensates for the direction and distance errors resulting from his damaged visual reaching network, by habitually opening his hand widely: the wider the hand aperture, the higher the probability of successfully acquiring the object.

Of course the present data cannot be generalized to other patients with optic ataxia. Indeed far from supposing that all optic ataxia patients will show a pattern similar to M.H.’s, we predict that the results of such testing with other patients will depend crucially on the extent and location of the lesion that causes the optic ataxia. Specifically, we would expect a primary deficit in grasping, as well as in reaching, when the optic ataxia is associated with lesions that include area aIPS, which is

known from lesion (Binkofski et al., 1998) and TMS studies (Tunik et al., 2005; Davare et al., 2007) to play a critical causal role in hand pre-shaping, but not in reaching (Rice et al., 2006). M.H.'s structural MRI is consistent with a spared aIPS. Figure 6 shows that although brain atrophy is clearly present in parts of the left hemisphere, it is more conspicuous within the posterior than the anterior portion of the IPS. Figure 6 shows axial and parasagittal slices taken from M.H.'s brain (which was aligned to the anterior/posterior commissure and transformed into Talairach space). We superimposed on these slices the activated locations found in previous fMRI investigations of grasping (in green: see Castiello & Begliomini, 2008) and reaching (in red: see Culham et al., 2008), using the Talairach coordinates of the left hemisphere only. It is quite clear that while activations for reaching overlap with M.H.'s lesion in the posterior IPS, activations for grasping lie within the more spared anterior IPS. Although anoxic lesions are difficult to outline given the presence of atrophy (Gale et al., 1999; Hopkins et al., 2006), it seems quite clear that M.H.'s grey and white matter in the left hemisphere is much more compromised within the more posterior reach-related than the more anterior grasp-related areas in the parietal lobe (figure 6b). Importantly, M.H.'s lesion within the medial and posterior portion of the parietal cortex corresponds remarkably well with the location of the left-hemisphere lesion overlap computed from a large sample of optic ataxia patients (yellow crosses: Karnath & Perenin, 2005). Of course, only functional MRI (in which we are planning to involve M.H. in the near future) can establish with certainty the functional integrity of these regions by demonstrating that (i) grasping tasks will activate the spared grey matter within the aIPS, and (ii) reaching tasks will fail to fully activate the medial posterior parietal lobe.

[Insert figure 6 about here]

Our results thus suggest that when optic ataxia is caused by a lesion mostly affecting the dorsomedial posterior portion of the parietal lobe alone, any associated impairments of hand pre-shaping will be a secondary consequence of making inaccurate reaching movements. In other words such patients can be regarded as having a rather pure visuomotor impairment of reaching alone, probably including several aspects of visual control during arm transport, such as obstacle avoidance (Schindler et al., 2004; Rice et al., 2008) and the use of online feedback (Gréa et al., 2002). Our experimental paradigm should enable unambiguous testing for primary grasp and transport deficits to be done with other optic ataxia patients in the future, thereby allowing a fuller and more precise description of their visuomotor profile.

Our arguments would be of direct relevance to the discovery by Perenin and Vighetto (1983, 1988) that misreaching was closely linked to impaired visuomotor control of hand orientation in their group of unilateral optic ataxia patients. A failure to orient the wrist correctly cannot conceivably be accounted for as a secondary consequence of misreaching, given that changes in hand orientation could never serve to compensate for poor reaching accuracy. Neurons selectively responsive to grasping, reaching and wrist orientation (Galletti et al., 2003, Fattori et al., 2009) have been found within visual area V6A within the parietal occipital cortex of macaque monkey, therefore it will be an interesting question for future research to determine whether the visual control of hand orientation can or cannot be dissociated from the visual control of reaching – or indeed from the control of grasping.

References

- Astafiev, S. V., Shulman, G. L., Stanley, C. M., Snyder, A. Z., Van Essen, D. C., & Corbetta, M. (2003). Functional organization of human intraparietal and frontal cortex for attending, looking, and pointing. *Journal of Neuroscience*, 23, 4689-4699.
- Bálint, R. (1909). Seelenlähmung des 'Schauens', optische Ataxie, räumliche Störung der Aufmerksamkeit. *Monatsschrift für Psychiatrie und Neurologie*, 25, 51-81.
- Bell, J.A. (1984) *Semmes-Weinstein monofilament testing for determining cutaneous light touch/deep pressure sensation*. The Star, November/December, 44.
- Berthier, N. E., Clifton, R. K., Gullapalli, V., McCall, D. D., & Robin, D. J. (1996). Visual Information and Object Size in the Control of Reaching. *Journal of Motor Behavior*, 28, 187-197.
- Binkofski, F., Dohle, C., Posse, S., Stephan, K. M., Hefter, H., Seitz, R. J., et al. (1998). Human anterior intraparietal area subserves prehension. A combined lesion and functional MRI activation study. *Neurology*, 50, 1253-1259.
- Castiello, U. (2005). The neuroscience of grasping. *Nature Reviews Neuroscience*, 6, 726-736.
- Castiello, U., & Begliomini, C. (2008). The cortical control of visually guided grasping. *Neuroscientist*, 14, 157-170.
- Cavina-Pratesi, C., Fattori, P., Galletti, C., Quinlan, D., Goodale, M. A., & Culham, J. (2006). Event-related fMRI reveals a dissociation in the parietal lobe between transport and grip components in reach-to-grasp movements *Society for Neuroscience Abstracts*, Atlanta, Georgia, 307.312

- Cavina-Pratesi, C., Goodale, M. A., & Culham, J. C. (2007). fMRI reveals a dissociation between grasping and perceiving the size of real 3D objects. *PLoS ONE*, 2(5), e424.
- Connolly, J. D., Andersen, R. A., & Goodale, M. A. (2003). fMRI evidence for a 'parietal reach region' in the human brain. *Exp. Brain Res.*, 153, 140-145.
- Crawford, J.R., & Garthwaite, P.H. (2002). Investigation of the single case in neuropsychology: Confidence limits on the abnormality of test scores and test score differences. *Neuropsychologia*, 40, 1196-1208.
- Crawford, J.R., & Garthwaite, P.H. (2004). Statistical methods for single-case research: Comparing the slope of a patient's regression line with the slopes of a control sample. *Cortex*, 40, 533-548
- Culham, J. C., Danckert, S. L., DeSouza, J. F. X., Gati, J. S., Menon, R. S., & Goodale, M. A. (2003). Visually-guided grasping produces fMRI activation in dorsal but not ventral stream brain areas. *Experimental Brain Research*, 153, 180-189.
- Culham, J. C., Gallivan, J., Cavina-Pratesi, C., & Quinlan, D. J. (2008). fMRI investigations of reaching and ego space in human superior parieto-occipital cortex. In R. L. Klatzky, B. MacWhinney & M. Behrmann (Eds.), *Embodiment, Ego-space and Action*. New York: Psychology Press, pp 247-274.
- Davare, M., Andres, M., Clerget, E., Thonnard, J.L., Olivier, E. (2007) Temporal dissociation between hand shaping and grip force scaling in the anterior intraparietal area. *Journal of Neuroscience*, 27, 3974-80.
- Fattori, P., Breveglieri, R., Marzocchi, N., Filippini, D., Bosco, A., and Galletti, C. (2009). Hand orientation during reach-to-grasp movements modulates neuronal

- activity in the medial posterior parietal area V6A. *Journal of Neuroscience*, 29, 1928-1936.
- Faugier-Grimaud, S., Frenois, C., & Stein, D. G. (1978). Effects of posterior parietal lesions on visually guided behavior in monkeys. *Neuropsychologia*, 16, 151-168.
- Ferrier, D. (1886). *The Functions of the Brain* (2 ed.). London: Smith, Elder.
- Ferrier, D. (1890). *Cerebral Localisation (The Croonian Lectures)*. London: Smith, Elder.
- Frey, S. H., Vinton, D., Norlund, R., & Grafton, S. T. (2005). Cortical topography of human anterior intraparietal cortex active during visually guided grasping. *Cognitive Brain Research*, 23, 397-405.
- Gale, S.D., Hopkins, R.O., Weaver, L.K., Bigler, E.D., Booth, E.J., Blatter, D.D. (1999). MRI, quantitative MRI, SPECT, and neuropsychological findings following carbon monoxide poisoning. *Brain Injury*. 13, 229-43.
- Gallese, V., Murata, A., Kaseda, M., Niki, N., & Sakata, H. (1994). Deficit of hand preshaping after muscimol injection in monkey parietal cortex. *NeuroReport*, 5, 1525-1529.).
- Galletti, C., Kutz, D.F., Gamberini, M., Breveglieri, R., and Fattori, P. (2003). Role of the medial parieto-occipital cortex in the control of reaching and grasping movements. *Experimental Brain Research*, 153, 158-170.
- González-Alvarez, C., Subramanian, A., & Pardhan, S. (2007). Reaching and grasping with restricted peripheral vision. *Ophthalmic and Physiological Optics*, 27, 265-274.
- Goodale, M. A., & Murphy, K. J. (1997). Action and perception in the visual periphery. In P. Thier & H.-O. Karnath (Eds.), *Parietal Lobe Contributions to Orientation in 3D Space* (pp. 447-461). Heidelberg: Springer-Verlag.

- Gréa, H., Pisella, L., Rossetti, Y., Desmurget, M., Tilikete, C., Grafton, S., et al. (2002). A lesion of the posterior parietal cortex disrupts on-line adjustments during aiming movements. *Neuropsychologia*, 40, 2471-2480.
- Harvey, M. (1995). Translation of 'Psychic paralysis of gaze, optic ataxia, and spatial disorder of attention' by Rudolph Bálint. *Cognitive Neuropsychology*, 12, 261-282.
- Holmes, G. (1918). Disturbances of visual orientation. *British Journal of Ophthalmology*, 2, 449-468.
- Hopkins, R.O., Woon, F.L. (2006). Neuroimaging, cognitive, and neurobehavioral outcomes following carbon monoxide poisoning. *Behavioural and Cognitive Neuroscience Reviews*. 5, 141-55.
- Jeannerod, M. (1984). The timing of natural prehension movements. *Journal of Motor Behavior*, 16, 235-254.
- Jeannerod, M. (1986). The formation of finger grip during prehension: a cortically mediated visuomotor pattern. *Behavioural Brain Research*, 19, 99-116.
- Jeannerod, M. (1986). Mechanisms of visuo-motor coordination: a study in normal and brain-damaged subjects. *Neuropsychologia*, 24, 41-78.
- Jeannerod, M. (1988). *The Neural and Behavioural Organization of Goal-Directed Movements*. Oxford: Oxford University Press.
- Jeannerod, M., Decety, J., & Michel, F. (1994). Impairment of grasping movements following bilateral posterior parietal lesion. *Neuropsychologia*, 32, 369-380.
- Jeannerod, M., Arbib, M. A., Rizzolatti, G., & Sakata, H. (1995). Grasping objects: the cortical mechanisms of visuomotor transformation. *Trends in Neurosciences*, 18, 314-320.

- Karnath, H. O., & Perenin, M. T. (2005). Cortical control of visually guided reaching: Evidence from patients with optic ataxia. *Cerebral Cortex*, 15, 1561–1569.
- Lamotte, R. H., & Acuña, C. (1978). Deficits in accuracy of reaching after removal of posterior parietal cortex in monkeys. *Brain Research*, 139, 309-326.
- Manning, H. & Tremblay, F. (2006) Age differences in tactile pattern recognition at the fingertip. *Somatosensory and Motor Research*, 23, 147-155.
- Milner, A. D., & Goodale, M. A. (2006). *The Visual Brain in Action* (Second ed.). Oxford: Oxford University Press.
- Perenin, M.-T., & Vighetto, A. (1983). Optic ataxia: a specific disorder in visuomotor coordination. In A. Hein & M. Jeannerod (Eds.), *Spatially Oriented Behavior* (pp. 305-326). New York: Springer-Verlag.
- Perenin, M.-T., & Vighetto, A. (1988). Optic ataxia: a specific disruption in visuomotor mechanisms. I. Different aspects of the deficit in reaching for objects. *Brain*, 111, 643-674.
- Prado, J., Clavagnier, S., Otzenberger, H., Scheiber, C., Kennedy, H., & Perenin, M. T. (2005). Two cortical systems for reaching in central and peripheral vision. *Neuron*, 48, 849-858.
- Rice, N. J., Edwards, M. G., Schindler, I., Punt, T. D., McIntosh, R. D., Humphreys, G. W., et al. (2008). Delay improves the obstacle avoidance deficit in optic ataxia. *Neuropsychologia*, 46, 1549-1557
- Rice, N. J., Tunik, E., & Grafton, S. T. (2006). The anterior intraparietal sulcus mediates grasp execution, independent of requirement to update: new insights from transcranial magnetic stimulation. *Journal of Neuroscience*, 26, 8176-8182.
- Riddoch, M. J., Humphreys, G. W., Jacobson, S., Pluck, G., Bateman, A., & Edwards, M. (2004). Impaired orientation discrimination and localisation following parietal

- damage: on the interplay between dorsal and ventral processes in visual perception. *Cognitive Neuropsychology*, 21, 597-623.
- Schenk, T., Baur, B., Steude, U., and Bötzel, K. (2003). Effects of deep brain stimulation on prehensile movements in PD patients are less pronounced when external timing cues are provided. *Neuropsychologia*, 41, 783-794.
- Schindler, I., Rice, N. J., McIntosh, R. D., Rossetti, Y., Vighetto, A., & Milner, A. D. (2004). Automatic avoidance of obstacles is a dorsal stream function: evidence from optic ataxia. *Nature Neuroscience*, 7, 779-784.
- Schlicht, E. J., & Schrater, P. R. (2007). Effects of visual uncertainty on grasping movements. *Experimental Brain Research*, 182, 47-57.
- Tanné-Gariépy, J., Rouiller, EM., Boussaoud, D. (2002) Parietal inputs to dorsal versus ventral premotor areas in the macaque monkey: evidence for largely segregated visuomotor pathways. *Experimental Brain Research*, 145:91-103.
- Wing, A. M., Turton, A., & Fraser, C. (1986). Grasp size and accuracy of approach in reaching. *Journal of Motor Behavior*, 18, 245-2.
- Winward, C.E., Halligan, P.W. & Wade, D.T. (2000) *Rivermead assessment of somatosensory performance*. Bury St. Edmonds: Thames Valley Test Company Limited.

Figure captions:

Figure 1: Schematic representation of the experimental set-up. Subjects sat facing the experimental board and were asked to reach out and grasp a rectangular object presented on the left (left panels) or right side (right panels) using their right (first and third rows) or their left (second and fourth rows) hand. Possible object locations are shown as black rectangles. For half of the experimental blocks, subjects were required to maintain central fixation (white star). The starting hand position was indicated by a small disc (white dot) which could be attached to the board at one of two positions, either near to the body or distant from the body. Outward movements were made from the starting position closer to the body (upper two panels), and inward ones from the starting position further away from it (lower two panels). The *Minibird* magnet (m) was located on the same side as the stimuli, in line with the fixation point.

Figure 2: Landing positions of the hand. The graphs depict the landing positions of the wrist marker at the end of the ballistic part of M.H.'s movements. "Horizontal plane" represents left-right space (left negative and right positive) while "Depth plane" represents distance from the body (negative near to the body and positive distant from the body). Coloured shapes depict M.H.'s landing positions (yellow circles: left hand, central fixation; red diamonds: right hand, central fixation; green triangles: right hand, free viewing). Grey squares depict the landing positions for the right hand of an age-matched control (I.D.) using central fixation. Data are plotted separately for outward (left panel) and inward (right panel) movements. For outward reaches the close and the far conditions are depicted by negative and positive depth values, respectively. Conversely, for inward reaches the close and far conditions are

depicted by positive and negative depth values, respectively. Black circles represent the calibrated mean landing position and the dotted rectangle around it represents the spatial variability associated with the fact that many landing positions are compatible with grasping objects. This spatial variability was computed graphically by using the largest value in length (8 cm) and depth (5 cm) of the two objects.

Figure 3: Mean Transport Errors. The graph illustrates the mean transport error (TE) for patient M.H. (black) and controls (white). 95% confidence error is plotted for controls only. TE is plotted for actions executed with the right hand during free viewing (left panel), with the right hand during central fixation (middle panel) and with the left hand during central fixation (right panel). Data are shown separately for objects in left vs right hemispace, for inward vs outward reaches and for close vs far movements. M.H.'s largest errors are seen when he reaches within right hemispace while fixating centrally, using his right hand to access objects presented far from the hand. Significant differences between M.H. and controls are indicated with an asterisk.

Figure 4: Variability of Transport Errors. The graph illustrates the variance of the transport error for patient M.H. (black) and controls (white). 95% confidence intervals are plotted for controls only. Variance scores are plotted for actions executed with the right hand during free viewing (left panel), with the right hand during central fixation (middle panel), and with the left hand during fixation (right panel). Data are shown separately for objects in left vs right space, for inward vs outward reaches and for objects close vs far from the hand. Significant differences between M.H. and controls are indicated with an asterisk.

Figure 5: Maximum grip aperture. The graph illustrates the mean MGA for M.H. (black) and controls (white). 95% confidence intervals are shown for controls only. Data are reported for the right hand during free viewing (left), the right hand during central fixation (middle) and with the left hand during fixation (right). The MGA data are plotted as a function of object size (large vs small), hemispace (left vs right), movement direction (outward vs inward) and distance (close vs far object). M.H. showed no effect of object size on MGA when using his right hand to grasp objects presented far from the hand within right hemispace. The only significant difference in handgrip scaling between M.H. and the controls (measured as the regression slope across the two object sizes) is marked with an asterisk.

Figure 6: Relationship between M.H.'s lesion and fMRI activations during reaching and grasping tasks. M.H.'s lesion is shown on axial and parasagittal high-resolution anatomical slices aligned to the anterior/posterior commissures and transformed into Talairach space. The left hemisphere shows some atrophy throughout, however this appears to be more pronounced in the posterior parts of the parietal cortex. fMRI activations for grasping (green) and reaching (red) are superimposed onto M.H.'s brain using the Talairach coordinates taken from Castiello and Begliomini, 2008 (Figure 3c) and from Culham et al. 2008 (Table 1 - reaching section), respectively. From each set of Talairach coordinates we extracted the lowest and highest X, Y and Z values in order to construct a rectangular area encompassing all the listed activations. For the grasping and reaching activations shown in the axial slices, the Z values are indicated by the number of slices shown, and the X and Y values are included within the green/red areas, respectively. Similarly, for the

reaching activations showed in the parasagittal slices, the X values are represented by the slices, and the Y and Z values are included within the red areas. We have limited the reconstruction to the left hemisphere. It is evident that while the “reaching” activations overlap completely with the M.H.’s more atrophic areas in the medial posterior parietal cortex, those for grasping lie within the apparently spared anterior portion of his parietal cortex. A magnified section of slice 36 highlights the anterior and the posterior parietal cortex showing the extent of the damage to both white and grey matter. It appears that while the more anterior portion of the parietal cortex (around and within the green square representing grasping activations) shows intact white and grey matter, the more posterior portion (within the red square representing reaching activations) appears seriously compromised. The yellow crosses show the location of left hemisphere lesion overlap computed for a large sample of optic ataxia patients (Karnath & Perenin, 2005, Figure 5a).

Outward Reaches

Left space

Right space

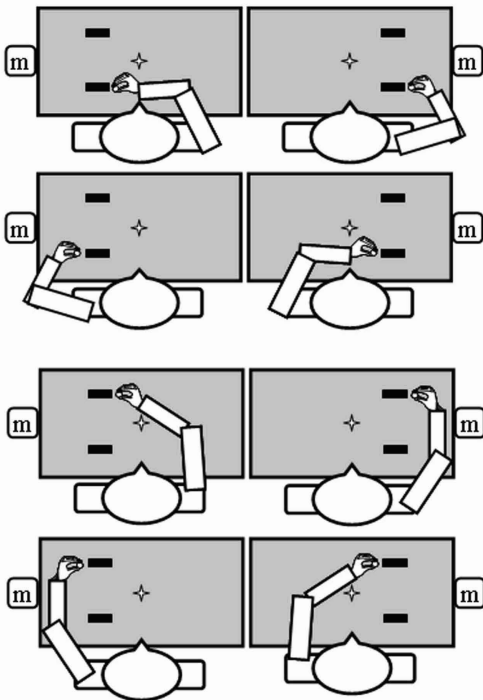
Right hand

Left hand

Inward Reaches

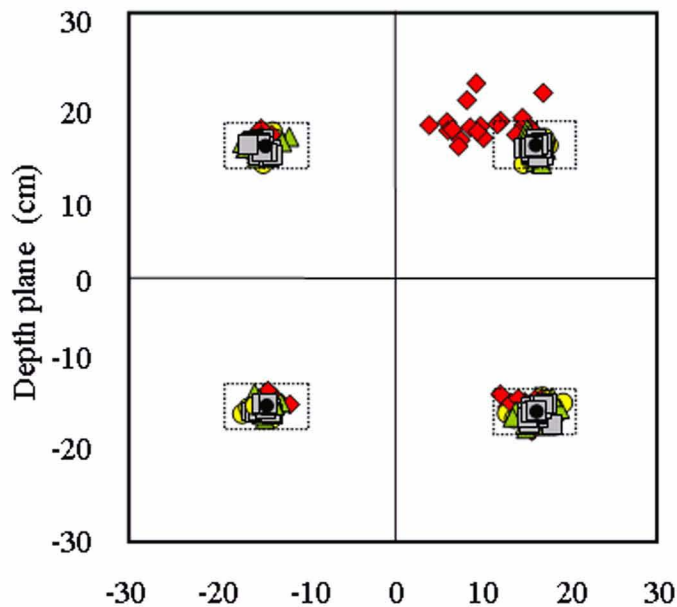
Right hand

Left hand

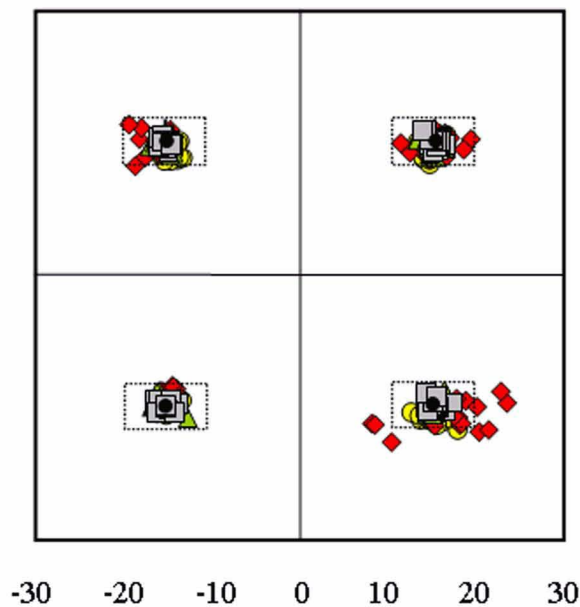


● MH left hand fixation ◆ MH right hand fixation ▲ MH right hand free viewing
■ AMC (ID) right hand fixation

Outward Movements

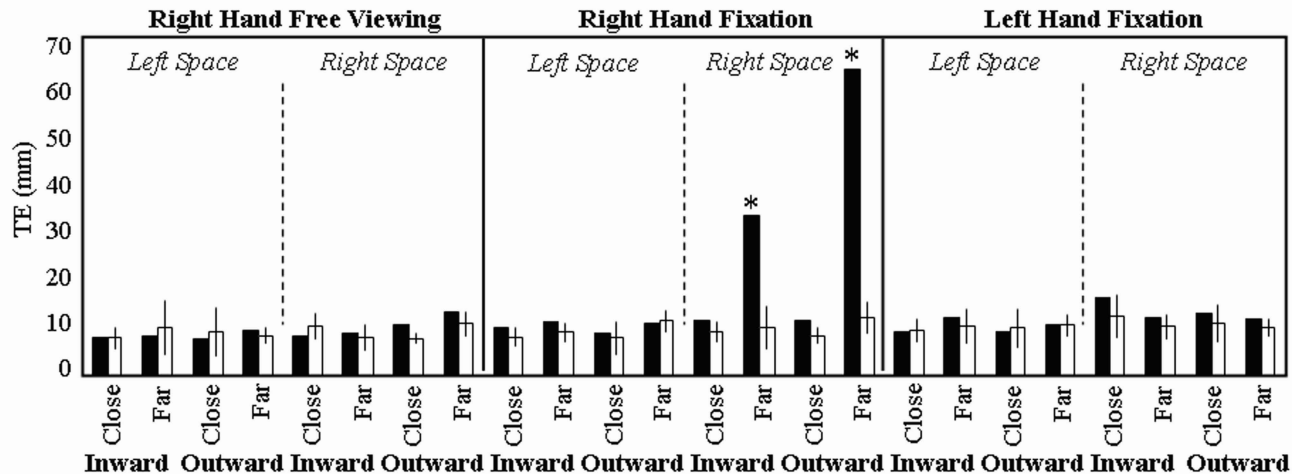


Inward Movements

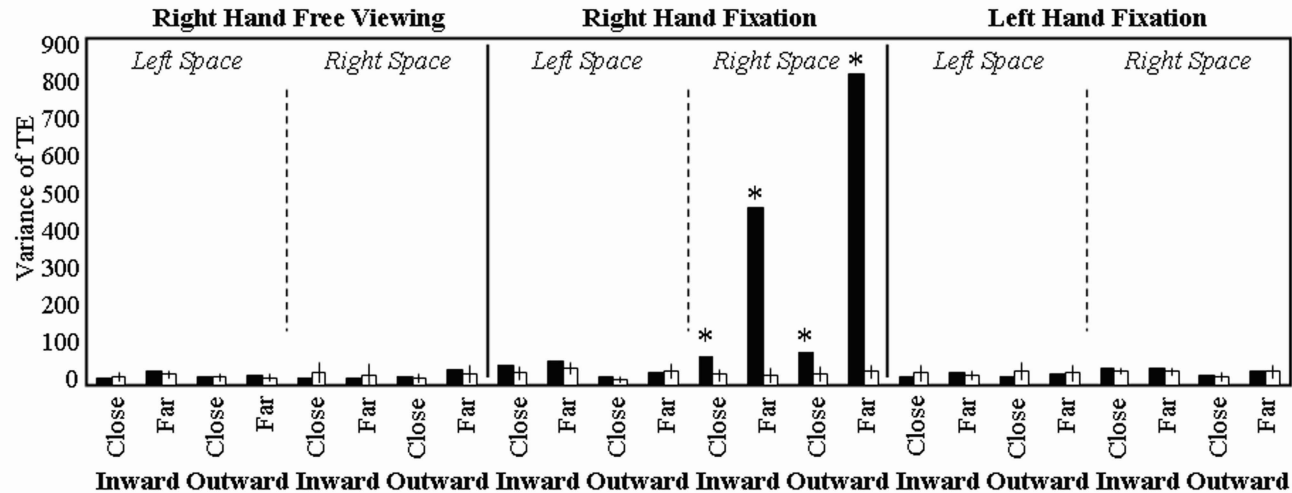


Horizontal plane (cm)

□ Age-matched controls ■ MH



□ Age-matched controls ■ MH



○ Age-matched controls ● MH

